

Andreia Horta\*<sup>1</sup>, Nádia Condesso<sup>1</sup>, Mário Maia Matos<sup>1,2</sup>, Amadeu Borges-Ferro<sup>1</sup>

1. Escola Superior de Tecnologia da Saúde de Lisboa, Instituto Politécnico de Lisboa, Lisboa, Portugal. 2. H&TRC – Health and Technology Research Center, ESTeSL – Escola Superior de Tecnologia da Saúde, Instituto Politécnico de Lisboa, Lisbon, Portugal

## 1. Introduction

The histological technique involves several steps to prepare tissues for microscopic analysis, with fixation being one of the key steps.<sup>(1)</sup> Formaldehyde is the most used fixing agent; however, it poses significant health risks and is classified as a Group 1 human carcinogen by the IARC and the NTP.<sup>(2)</sup> This concern has prompted the search for safer alternatives.

This study aims to identify a less harmful natural substitute for formaldehyde that can reduce or eliminate exposure to this hazardous reagent. To achieve this objective, a systematic review explored the potential of natural fixatives that can perform similar functions with lower toxicity.

## 2. Methodology

The process of selecting articles was carried out following the PRISMA methodology.<sup>(3)</sup> Articles were searched in the PubMed and Web of science databases, using 5 combinations of the keywords “natural fixatives”; “tissue fixation”; “honey fixatives”; “sugar fixatives”; “jaggery fixatives”, and using the Boolean operators “AND” or “OR” (Figure 1). A filter was added so that only articles published between the years 2000-2024 were shown. Duplicate articles were removed using the Rayyan application and the exclusion criteria were applied. Finally, quality control of articles was performed based on Harden A. Mixed-Methods Systematic Reviews: Integrating Quantitative and Qualitative Findings.<sup>(4)</sup> A total of 1030 articles were identified through the search, however, only 8 articles were considered eligible and included in the review (Figure 2).

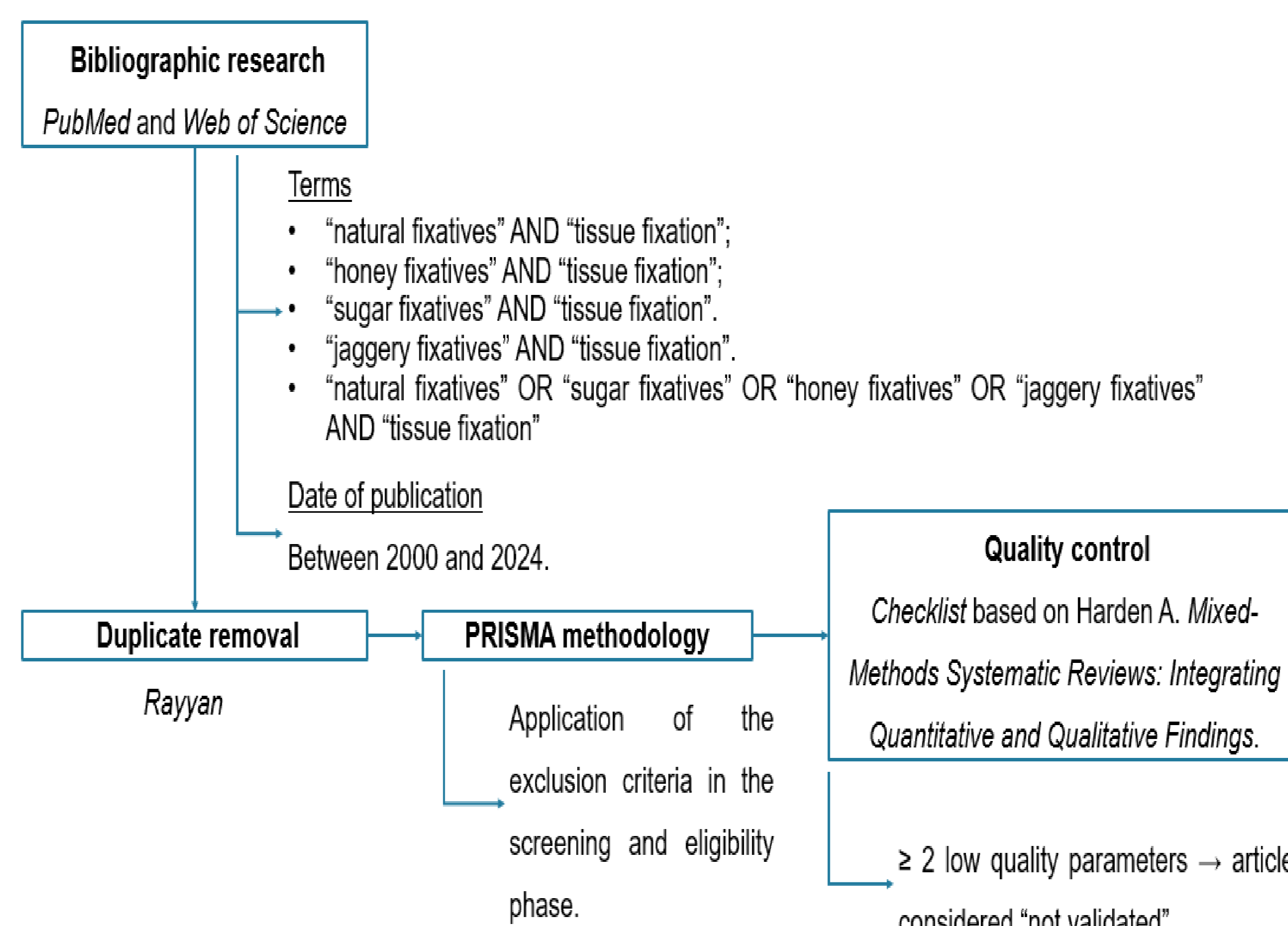


Figure 1: Flow diagram that illustrates the steps developed for the systematic review elaboration process.

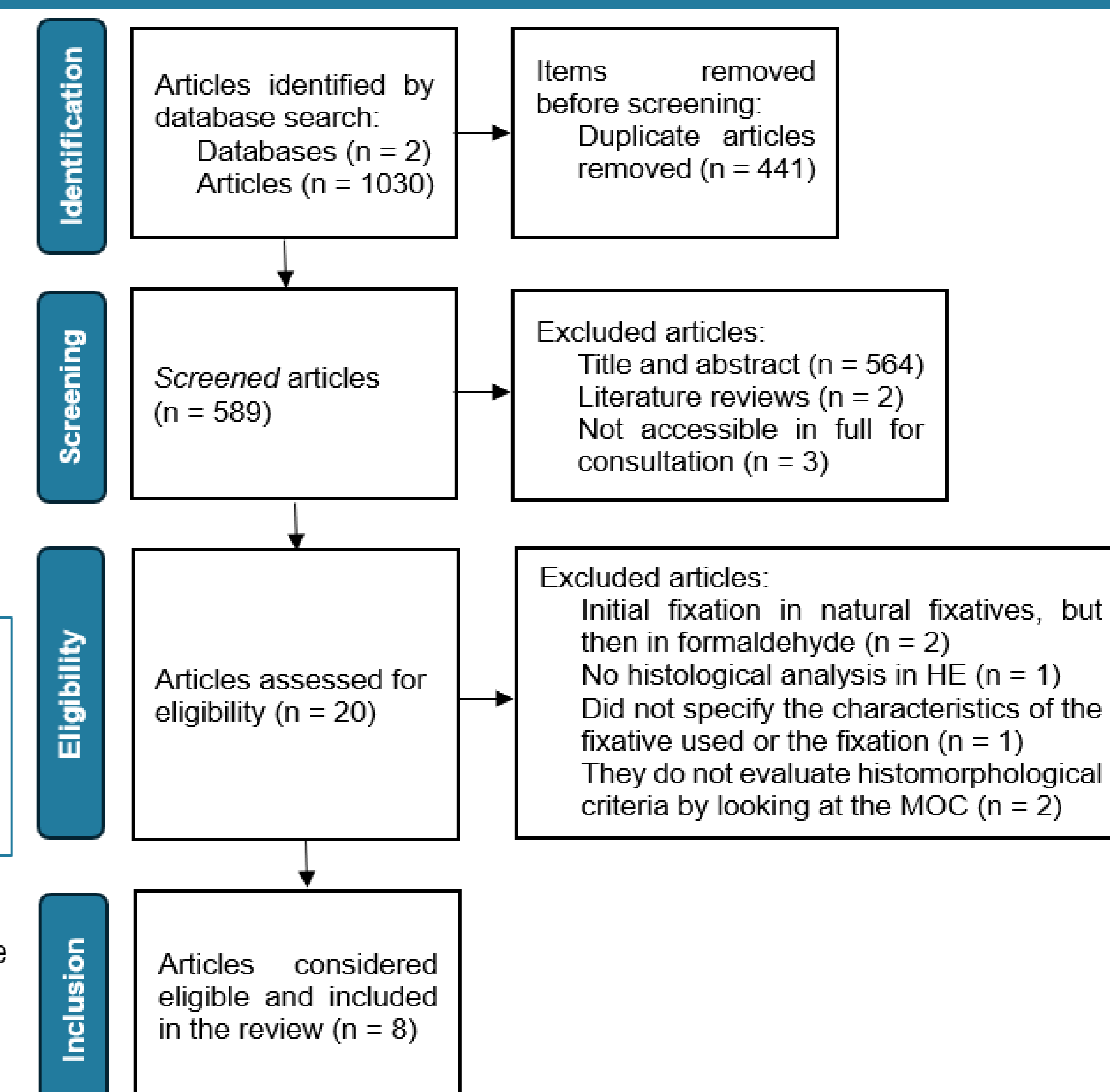


Figure 2: Flow diagram of the articles included in the Systematic Literature Review.

## 3. Results and Discussion

The articles were analysed for their natural fixative characteristics, fixation conditions, tissue types, and evaluation parameters (Table 1). Among the reviewed articles, five alternative natural fixatives were identified – honey, jaggery, khandsari, sugar and Aloe vera.

The results obtained indicate that honey stands out as a potential natural substitute for formaldehyde, having performed comparably to formaldehyde in most of the studies analyzed.<sup>(1, 5, 6, 7)</sup> However, some limitations were observed, such as the hyalinized appearance of collagen fibres<sup>(6, 7)</sup> and inadequate cytoplasmic staining<sup>(1)</sup> in certain cases. Jaggery showed contradictory results, performing similarly to formaldehyde in some studies<sup>(2, 8)</sup>, while in others there were statistically significant differences<sup>(9)</sup>. Despite this variability, its advantage over honey is its low cost<sup>(8)</sup>, making it an economically viable alternative. Sugar, on the other hand, performed less well than formaldehyde in all the studies analyzed and is considered a poor candidate to replace it<sup>(2, 8, 10)</sup>. Aloe vera and khandsari, in contrast, obtained encouraging results, especially khandsari, which showed no statistically significant differences compared to formaldehyde<sup>(9)</sup>. However, the scarcity of studies on these two fixatives<sup>(9, 10)</sup> prevents definitive conclusions as to their applicability as viable alternatives to formaldehyde.

Table 1: Summary table from the systematic review of the analysis of the collected articles. Legend: ✓ there were no statistically significant differences; ✗ there were statistically significant differences

Source	Sample	Fixatives	Duration	Temperature	Results
Özkan et al., 2012 <sup>(5)</sup>	7 different fresh human tissues	Honey 10%; Formaldehyde	24 hours	Room temperature	H&E: Appropriate results for diagnosis, showed good cell preservation, except in endometrial tissues. ✗ nuclear morphology, with formaldehyde fixed tissues achieving the best results. Gomori one-step trichrome staining: ✗ IHQ (Vimentin and Ki-67): ✓
Patil et al., 2013 <sup>(8)</sup>	5 fresh pieces obtained from the buccal mucosa of a goat	Honey 20%; Jaggery 30%; Sugar 20%; Formaldehyde; Distilled water	24 hours	Room temperature	H&E: Formaldehyde fixed tissues showed the best results, followed by jaggery, honey, sugar and distilled water, with irregular coloration and tissue folds in those fixed in honey and sugar.
Lalwani et al., 2015 <sup>(6)</sup>	36 fragments obtained from 12 different human tissues	Unprocessed honey 10%; Processed honey 10%; Formaldehyde	24 hours	Room temperature	H&E: Appropriate results for diagnosis. ✓ between the honey and formaldehyde fixed tissues, but the honey fixed tissues showed "out-of-focus" areas and slit-like spaces in the epithelial tissues and hyalinized collagen fibers.
Srii et al., 2017 <sup>(7)</sup>	10 tissue samples from gingival biopsies	Honey 10%; Formaldehyde	24 hours	25-27°C	H&E: Masson's trichrome and Van Gieson: ✓ between the honey and formaldehyde fixed tissues, but the honey fixed tissues exhibited a more hyalinized appearance of the collagen fibres. IHQ (Vimentin and Pancytokeratin): ✓
Chittamsetti et al., 2018 <sup>(9)</sup>	90 tissue samples from oral surgery	Jaggery 30%; Khandsari 30%; Formaldehyde	24 hours	-	H&E: Tissues fixed in jaggery and khandsari with folds and in jaggery homogenization with loss of differentiation between the structures. ✓ between the khandsari and formaldehyde fixed tissues. ✗ between the jaggery and khandsari fixed tissues and the jaggery and formaldehyde fixed tissues and those fixed in khandsari, and formaldehyde showed better results, respectively.
Bhattacharyya et al., 2018 <sup>(2)</sup>	40 fragments obtained from a fresh goat's tongue	Honey 100%; Jaggery 100%; Sugar 100%; Formaldehyde; Distilled water	24, 48 and 72 hours	Room temperature	H&E: ✓ between the jaggery and formaldehyde fixed tissues at all fixation times. ✗ in some parameters of tissues fixed in honey, sugar and in all parameters of tissues fixed in distilled water, for all fixation times, with formaldehyde showing the best results.
Alwahaibi et al., 2023 <sup>(11)</sup>	81 fragments obtained from the liver, kidney and stomach organs of 3 Wister rats	Neutral buffered Sumer honey 10% and alcoholic; Neutral buffered Date honey 10% and alcoholic; Formaldehyde	24 hours	18-23°C	H&E: ✓ between the honey and formaldehyde fixed tissues except for cytoplasmic staining and the preservation of cell morphology, which was superior in formaldehyde-fixed tissues. JMS: PAS; IHQ (Vimentin): ✓ Gordon and Sweets: tissues fixed in honey with weak staining of the reticulin fibers.
Narwal et al., 2023 <sup>(10)</sup>	50 tissue fragments obtained from 10 skin samples from 10 cadavers	Processed honey 20%; Jaggery 30%; Sugar 20%; Aloe vera 20%; Formaldehyde	24 hours	Room temperature	H&E: The best results were obtained from tissues fixed in formaldehyde, followed by Aloe vera, sugar, honey and jaggery, with those fixed in honey and jaggery showing poor morphology and abundant folds. Shrinkage: similar between tissues fixed in formaldehyde and Aloe vera, higher in those fixed in sugar and maximum in those fixed in jaggery.

## 4. Conclusions

The data analyzed suggests that honey and jaggery are the most promising natural fixatives to replace formaldehyde, although the variability in the results of the studies reviewed prevents a definitive substitute from being determined. On the other hand, sugar showed unsatisfactory performance, while Aloe vera and khandsari, despite encouraging results, lack further validation due to the small number of studies available.

Although no particularly relevant limitations were identified, some

inconsistencies were observed in the reproducibility of the studies and in the application of statistical inference, so future investigations should prioritize more standardized and detailed methodological approaches. They should also analyze different histological stains, a greater variety of immunohistochemical markers, the integrity of nucleic acids and proteins and the penetration power of natural fixatives in tissues, in order to contribute to a better understanding of their viability as alternatives to formaldehyde.

## 5. References

- Alwahaibi N, Al Dhahli B, Al Issaei H, Al Wahaibi L, Al Sinawi S. Effectiveness of neutral honey as a tissue fixative in histopathology. *F1000Research*. 2023; 11:1014.
- Bhattacharyya A, Gupta B, Singh A, Sah K, Gupta V. Probing natural substitute for formalin: Comparing honey, sugar, and jaggery syrup as fixatives. *National Journal of Maxillofacial Surgery*. 2018; 9(1):14-21.
- PRISMA. PRISMA 2020 [Internet]. 2024. Disponível em: <https://www.prisma-statement.org/prisma-2020>
- Harden A. *Mixed-Methods Systematic Reviews: Integrating Quantitative and Qualitative Findings*. Focus: Technical Brief. 2010; 25.
- Özkan N, Şalva E, Çakalağaoğlu F, Tüzüner B. Honey as a substitute for formalin? *Biotechnic & Histochemistry*. 2012; 87(2):148-153.
- Lalwani V, Surekha R, Vanishree M, Koneru A, Hunasgi S, Ravikumar S. Honey as an alternative fixative for oral tissue: an evaluation of processed and unprocessed honey. *Journal of oral and maxillofacial Pathology*. 2015; 19(3): 342-347.
- Srii R, Peter C D, Haragannavar V C, Shashidara R, Sridhara S U, Srivatsava S. Bee Honey as a Safer Alternative for Routine Formalin Fixation. *Kathmandu University Medical Journal*. 2017; 60(4):308-312.
- Patil S, Premalatha B, Rao R S, Ganavi B. Revelation in the field of tissue preservation - a preliminary study on natural formalin substitutes. *Journal of International Oral Health*. 2013; 5(1):31-38.
- Chittamsetti S, Nallamala S, Sravya T, Guttikonda V R, Manchikatta P K, Kondamari S. Natural substitutes for : A boon to histopathology!! *Journal of Oral and Maxillofacial Pathology*. 2018; 22(1):143.
- Narwal A, Singh E, Duhan J, Dhatarwal S K, Singh V, Kamboj M, Devi A, Gupta S. Qualitative assessment of Aloe vera as natural tissue fixative: An institutional study. *Journal of Oral and Maxillofacial Pathology*. 2023; 27(1):33-38.