



INSTITUTO POLITÉCNICO DE LISBOA  
ESCOLA SUPERIOR DE TECNOLOGIA DA SAÚDE DE  
LISBOA

**CHALLENGES OF MAGNETIC RESONANCE IMAGING IN  
THE CHILD: EFFECTS OF CONSCIOUSNESS  
INDUCTION DECAY IN ABDOMINO-MRI**

Bárbara Alexandra da Silva Poiares

Supervisor: Maria Margarida do Carmo Pinto Ribeiro, Ph.D., Prof.  
Adjunta Unidade de Ensino e Investigação em Imagem Médica e  
Terapia

Mestrado em Radiações Aplicadas às Tecnologias da Saúde  
Imagem por Ressonância Magnética

*Lisbon, July 2021*

INSTITUTO POLITÉCNICO DE LISBOA  
ESCOLA SUPERIOR DE TECNOLOGIA DA SAÚDE DE  
LISBOA

**CHALLENGES OF MAGNETIC RESONANCE IMAGING IN  
THE CHILD: EFFECTS OF CONSCIOUSNESS  
INDUCTION DECAY IN ABDOMINO-MRI**

Bárbara Alexandra da Silva Poiares

Supervisor: Maria Margarida do Carmo Pinto Ribeiro, Ph.D., Prof.  
Adjunta Unidade de Ensino e Investigação em Imagem Médica e  
Terapia

Júri:

Presidente: Mestre/Especialista Marco Alexandre Caetano

Arguente: Doutora Maria Luisa Gomes Pinto Nogueira

Arguente: Mestre/Especialista Filomena Isabel Gonçalves Batalha

Mestrado em Radiações Aplicadas às Tecnologias da Saúde  
Imagem por Ressonância Magnética

*Lisbon, July 2021*

© Copyright by Bárbara Poiares, ESTeSL/IPL, IPL

A Escola Superior de Tecnologia da Saúde de Lisboa tem o direito, perpetuo e sem limites geográficos, de arquivar e publicar esta dissertação através de exemplares impressos reproduzidos em papel ou de forma digital, ou por qualquer outro meio conhecido ou que venha a ser inventado, e de a divulgar através de repositórios científicos e de admitir a sua cópia e distribuição com objetivos educacionais ou de investigação, não comerciais, desde que seja dado critério ao autor e editor e que tal não viole nenhuma restrição imposta por artigos publicados que estejam incluídos neste trabalho.



## Acknowledgments

I would like to start by thanking to my mentor Professor Maria Margarida do Carmo Pinto Ribeiro, for all the help and advice that she provide in this process. For giving me support to conclude this work with all the challenges and adversities.

I would also like to show my appreciation to my manager Rajinder Sandhu from the Leicester Royal Infirmary, for her time and guidance for this study. For helping me to obtain the approval to acquire all the data. Thank you for all your patient and kindness. Could not finish this paper without her support.

To all my colleagues and Radiologists that participate on this study, thank you for your time and readiness to join me on this journey.

Also, to Professor Luís Freire, thank you for all the understanding and accessibility through all this time.

A big thank you to my family and closest friend, specially to Ana Pereira and Mafalda Fontes, for all the companionship and support in the less good days.

To my mother, for pushing me to finish this work and to accomplish my goals. For all the love, perseverance, and support. She always gives the best advice.



## Abstract

**Abstract:** The demand for Magnetic Resonance Imaging (MRI) in the paediatric population is increasing every day as it is a valuable tool for clinical and diagnostic information. An MRI scan in a child can be challenging. The anxiety can reduce the compliance of the child and in certain patients, the inability of following instructions together with movement artifacts can degrade the image quality. In these cases, the use of sedation or General Anaesthetic (GA) is required to achieve a diagnostic image.

**Objectives:** This study aimed to analyse the images quality of MR Enterogram (MRE) studies with and without general anaesthetic or sedation. Furthermore, to reduce the number of MRI exams with General Anaesthetic (GA) or sedation and empower the Radiographer professional skills in MRI studies performance, this study intent to know more about the process to generate a team of good practices in the patient preparation for the child in this hospital group.

**Methods:** This study was performed in the University Leicester Hospitals (UHL). The selection of the sample was based on the age group and the type of scan. In total, 73 exams were evaluated. The patients were between the age range of 4-16 years that had abdominal scans. A questionnaire was performed to analyze the opinion of four clinical assessors about the image quality and diagnostic value of each examination. The kappa Fleiss statistical test was used to analyze the agreement within the observers.

**Results:** Analysing the *kappa* value in table 7 that provides the degree of agreement between raters, suggests that the exams that were classified as being 'Excellent for Diagnostic', most or all the raters agreed with the image quality. Opposite, in the 'Optimal' or 'Sub-optimal' classifications, it is possible to conclude that the raters categorization differs. For the age group [4,8], the group in which the scans were mainly performed under GA, the major comment was "artifacts presence". Mostly artifacts noted are breathing artifacts.

**Conclusion:** This study demonstrates the importance to compare the MRE images with and without sedation or GA and explore the risk-benefit in the use of techniques to decrease, whenever possible, the consciousness decay in this population replacing these procedures by techniques less invasive. Also, is essential in paediatric MRI scans that the Radiographer feels confident enough and his aware of the challenges that can occur with these patients.

**KEYWORDS:** Paediatric Abdominal MRI; Sedation; General Anaesthetic.

## Resumo

**Resumo:** A procura da Imagem por Ressonância Magnética na população pediátrica tem vindo a aumentar diariamente sendo uma ferramenta de elevado valor diagnóstico. Contudo, este exame pode ser um grande desafio quando realizado em crianças. A ansiedade reduz a capacidade da criança de permanecer imóvel para o exame e, em alguns dos pacientes, a inability de obedecer a instruções, gerando artefactos de movimento que podem degradar a qualidade da imagem. Nestes casos, o uso de sedação ou de anestesia geral pode ser necessária a fim de obter um exame diagnóstico.

**Objetivos:** O objetivo principal deste estudo é reduzir o número de exames de Ressonância Magnética submetidos a anestesia geral ou sedação e fortalecer as aptidões profissionais dos técnicos de Radiologia assim como criar um grupo de boas práticas na preparação da criança para o exame.

**Métodos:** Este estudo foi realizado no *University Leicester Hospitals* (UHL). A seleção da amostra foi baseada na idade e no tipo de exame. No total, 73 exames foram avaliados, em crianças entre os 4 e 16 anos de idade que efetuaram ressonâncias abdominais submetidas ou não a anestesia geral. Um questionário foi realizado de forma a avaliar a opinião de quatro avaliadores acerca da qualidade de imagem e valor diagnóstico. Foi usado o teste estatístico *kappa Fleiss* para observar a concordância entre observadores.

**Resultados:** Pela análise dos valores de *kappa* na tabela 7 que possui o grau de concordância entre os observadores, sugere que os exames classificados como '*Excellent for Diagnostic*', quase ou todos os avaliadores estavam em concordância com a classificação da qualidade da imagem. Contrariamente, os exames classificados de '*Optimal*' ou '*Sub-optimal*', é possível concluir que os observadores diferem na sua categorização. No grupo de idade de [4,8[, grupo em que os exames foram maioritariamente realizados sobre anestesia geral, o cometário mais referenciado foi relativamente a artefactos de respiração.

**Conclusão:** Este estudo demonstra a importância na comparação de imagens de Enterogramas com e sem o uso de sedação ou anestesia geral, de forma a explorar o risco-benefício. Igualmente, é essencial que em exames pediátricos de Ressonância Magnética, o técnico se sinta confiante e esteja consciente dos desafios que podem ocorrer com crianças.

**PALAVRAS-CHAVE:** Ressonância Magnética pediátrica abdominal; Sedação; Anestesia Geral.

# Index

|  |      |
|--|------|
| <b>Acknowledgments</b> .....   | v    |
| <b>Abstract</b> .....  | vii  |
| <b>Resumo</b> .....  | viii |
| <b>Index</b> .....   | ix   |
| <b>List of abbreviations, acronyms and units</b> .....                     | xi   |
| <b>List of figures</b> .....   | xiii |
| <b>List of tables and graphs</b> .....                                     | xiv  |
| <b>List of attachments</b> .....   | xv   |
| <b>1 Introduction</b> .....  | 1    |
| <b>1.1 Relevance of the study in the MRI field</b> .....                   | 1    |
| <b>2 Framework</b> .....   | 5    |
| <b>2.1 Small bowel pathology</b> .....                                     | 6    |
| <b>2.2 Techniques in paediatric MRI</b> .....                              | 7    |
| <b>2.3 MRI abdominal artifacts</b> .....                                   | 9    |
| 2.3.1 B1 inhomogeneity .....   | 9    |
| 2.3.2 Aliasing or phase wrapping artifacts.....                            | 10   |
| 2.3.3 Chemical shift artifact.....   | 10   |
| 2.3.4 Patient-related artifacts.....                                       | 11   |
| <b>2.4 General anaesthetic or sedation – complications and risks</b> ..... | 14   |
| <b>2.5 Paediatric MRI at University Hospitals of Leicester</b> .....       | 16   |
| <b>2.6 MR Enterogram</b> .....   | 17   |
| <b>2.7 MR Enterogram at University Hospitals of Leicester</b> .....        | 21   |
| <b>2.8 MRI department in the University Hospitals of Leicester</b> .....   | 26   |
| <b>2.9 Objectives</b> .....  | 26   |
| <b>3 Materials and methods</b> .....                                       | 28   |
| <b>3.1 Study design</b> .....  | 28   |
| <b>3.2 Materials</b> .....   | 28   |
| <b>3.3 Population and sample</b> .....                                     | 28   |
| <b>3.4 Sample characterization</b> .....                                   | 28   |

|            |   |    |
|------------|---|----|
| <b>3.5</b> | <b>Variables</b> .....                                | 29 |
| <b>3.6</b> | <b>Data collection</b> .....                          | 29 |
| <b>3.7</b> | <b>Ethical approaches</b> .....                       | 30 |
| <b>3.8</b> | <b>Methods of data processing and treatment</b> ..... | 30 |
| <b>4</b>   | <b>Results</b> .....                                  | 32 |
| <b>5</b>   | <b>Analysis and discussion of results</b> .....       | 36 |
| <b>6</b>   | <b>Conclusions</b> .....                              | 39 |
| <b>7</b>   | <b>References</b> .....                               | 42 |
| <b>8</b>   | <b>Attachments</b> .....                              | 48 |

## List of abbreviations, acronyms and units

|               |   |
|---------------|---|
| <b>ADC</b>    | Apparent Diffusion Coefficient                  |
| <b>ALARA</b>  | As Low As Reasonably Achievable                 |
| <b>BH</b>     | Breath Holding                                  |
| <b>BLS</b>    | Basic Life Support                              |
| <b>bSSFP</b>  | balanced Steady-State Free Precession           |
| <b>cm</b>     | Centimetres                                     |
| <b>CT</b>     | Computed Tomography                             |
| <b>CD</b>     | Crohns' disease                                 |
| <b>CNR</b>    | Contrast-to-Noise Ratio                         |
| <b>CPD</b>    | Continuing Professional Development             |
| <b>CSF</b>    | Cerebrospinal Fluid                             |
| <b>DCE</b>    | Dynamic Contrast-Enhanced                       |
| <b>DWI</b>    | Diffusion-Weighted Imaging                      |
| <b>ED</b>     | Emergency Department                            |
| <b>EPI</b>    | Echo-Planar Imaging                             |
| <b>ETL</b>    | Echo Train Length                               |
| <b>FS</b>     | Fat Saturation                                  |
| <b>FSE</b>    | Fast Spin Echo                                  |
| <b>FIESTA</b> | Fast Imaging Employing Steady-state Acquisition |
| <b>FISP</b>   | Fast Imaging with Steady-state Precession       |
| <b>FOV</b>    | Field of View                                   |
| <b>GA</b>     | General Anaesthetic                             |
| <b>GRE</b>    | Gradient Echo                                   |
| <b>GE</b>     | General Electric                                |
| <b>GH</b>     | Glenfield Hospital                              |
| <b>GI</b>     | Gastro-Intestinal                               |
| <b>IBD</b>    | Inflammatory Bowel Diseases                     |
| <b>LGH</b>    | Leicester General Hospital                      |
| <b>LRI</b>    | Leicester Royal Infirmary                       |
| <b>min</b>    | Minutes   |
| <b>MRI</b>    | Magnetic Resonance Imaging                      |
| <b>MRE</b>    | Magnetic Resonance Imaging Enterogram           |
| <b>NEX</b>    | Number of excitations                           |

|                  |  |
|------------------|--|
| <b>NSF</b>       | Nephrogenic Systemic Fibrosis  |
| <b>NHS</b>       | National Health System   |
| <b>PACS</b>      | Picture Archiving and Communication System                                   |
| <b>PROPELLER</b> | Periodically Rotated Overlapping Parallel Lines with Enhanced Reconstruction |
| <b>RARE</b>      | Rapid Acquisition with Relaxation Enhancement Reconstruction                 |
| <b>sec</b>       | Seconds  |
| <b>SNR</b>       | Signal-to-Noise Ratio  |
| <b>SB</b>        | Small Bowel  |
| <b>SPGR</b>      | Spoiled Gradient Echo  |
| <b>SSFP</b>      | Steady-State Free Precession   |
| <b>STIR</b>      | Short Time Inversion Recovery  |
| <b>T</b>         | Tesla  |
| <b>TE</b>        | Echo Time  |
| <b>TR</b>        | Repetition Time  |
| <b>TSE</b>       | Turbo Spin-Echo  |
| <b>T1W</b>       | Time 1-Weighted  |
| <b>T2W</b>       | Time 2-Weighted  |
| <b>UC</b>        | Ulcerative Colitis   |
| <b>UHL</b>       | University Hospital of Leicester   |

## List of figures

- Figure 2.1 -** Axial T2-weighted images in a paediatric abdominal imaging. Aliasing artifact can be observed. Source: UHL Page 10
- Figure 2.2 -** Demonstration of the chemical Shift artifact at a fat-water interface (34). Page 11
- Figure 2.3 -** Coronal FIESTA FS cine stack in a paediatric MRE. It can be observed in the image a dark line that characterizes a chemical shift artifact. Source: UHL Page 11
- Figure 2.4 -** Coronal STIR (left image) and Axial T1 FS (right image) showing movement and breathing artifacts in paediatric abdominal scans. Source: UHL Page 12
- Figure 2.5 -** Coronal (left image) and Sagittal (right image) FIESTA FS sequences from the same patient. These show a not good preparation of the patient has the stomach and the bowel are full of air and the images become non diagnostic. Source: UHL Page 18
- Figure 2.6 -** Coronal FIESTA FS plane from a cine stack (left image) and True FISP (right image) sequences from two different MRE with oral contrast in paediatric patients. The bowel demonstrates a good distension and wall enhancement. Source: UHL Page 19
- Figure 2.7 -** Coronal FIESTA FS from a cine stack sequence (left image) and coronal True FISP sequence (right image) from two different paediatric MRE. In the image it can be observed the inflammation of the terminal ileum (arrows). Source: UHL Page 20

## List of tables and graphs

|                    |   |         |
|--------------------|---|---------|
| <b>Table 1.1</b> - | Tissue weighting factor published in ICR Publications 60 and 103 (13).                          | Page 2  |
| <b>Table 2.1</b> - | Enterogram protocol for the GE Discovery scanner.   | Page 22 |
| <b>Table 2.2</b> - | Enterogram protocol for the GE Optima scanner.  | Page 22 |
| <b>Table 2.3</b> - | Protocol sequences for Siemens Aera scanner.  | Page 23 |
| <b>Table 3.1</b> - | Interpretation of k values (53).  | Page 31 |
| <b>Table 4.1</b> - | Exams that required or not general anaesthetic (GA) per group age.                              | Page 32 |
| <b>Graph 4.2</b> - | Graphic illustrations of the clinical requirements in the age groups.                           | Page 32 |
| <b>Graph 4.3</b> - | Graphic illustration of the percentage of the sequences used in the exams studied.              | Page 33 |
| <b>Table 4.4</b> - | Classification given by the four raters to each exam per age.                                   | Page 34 |
| <b>Table 4.5</b> - | Outputs from Fleiss' Kappa analysis tool.   | Page 34 |
| <b>Table 4.6</b> - | Kappa and p-values for the classification presented after applying the Fleiss' Kappa test       | Page 34 |
| <b>Table 4.7</b> - | Answers of the raters regarding the exam's comments, separate by categories and per age groups. | Page 35 |

## List of attachments

|                        |  |         |
|------------------------|--|---------|
| <b>Attachment I:</b>   | Authorization letter from the MRI Superintendent for the data collection.  | Page 48 |
| <b>Attachment II:</b>  | Authorization email by the Clinical Audit Team regarding ethical concerns.   | Page 49 |
| <b>Attachment III:</b> | Email from the Ethic Board of ESTESL approving the project.  | Page 50 |
| <b>Attachment IV:</b>  | MRI safety questionnaire of Cross-Sectional Department at University Hospital of Leicester (UHL)                   | Page 52 |
| <b>Attachment V:</b>   | Consent form for general anaesthetic procedures of Imagology Department at University Hospital of Leicester (UHL). | Page 53 |
| <b>Attachment VI:</b>  | Example of the questionnaire performed by the assessors with a <i>Likert</i> scale of three classifications        | Page 54 |
| <b>Attachment VII:</b> | Checklist of good practices and strategies for paediatric MRI exams.   | Page 56 |

# 1 Introduction

The demand for Magnetic Resonance Imaging (MRI) in the paediatric population is increasing every day as it is a valuable tool for clinical and diagnostic information. The non-use of ionizing radiation, the high contrast between soft tissues and the capacity of performing multiplanar acquisitions, means this is the perfect modality for paediatric patients in opposition to Computed Tomography (CT)(1–3).

An MRI scan in a child can be challenging. The anxiety can reduce the compliance of the child and in certain patients, the inability of following instructions together with movement artifacts can degrade the image quality (1,4,5). In these cases, the use of sedation or general anaesthetic (GA) is required to achieve a quality's image to diagnostic. However, this procedure has a high risk of complications, like hypoxia and idiopathic hyperactive, as also high costs, always requiring an anaesthetic team to be present during the exam and in the patient recovery, a dedicated space, onerous materials, and a set of logistic resources. The cooperation is predominantly needed in children with neurologic disabilities associated with epilepsy, late development, and hyperactivity (2,4,6–8).

In abdominal exams, besides the difficulties described above, other variables need to be considered such as the exam preparation (nil by mouth, oral contrast), patient size and breathing instructions, so that each protocol needs to be adapted to the pathology, age and child behaviour and region of interest being studied (9).

## 1.1 Relevance of the study in the MRI field

MRI is considered the modality of choice for paediatric patients given the potentially harmful effects of ionizing radiation associated with other Radiological modalities. MRI requires no ionizing radiation, whereas CT, for example, is the single largest source of medical radiation exposure in children and adults (10–12). Children are more susceptible to radiation-induced risks than adult patients owing to their more rapidly growing tissues, especially breast, gonadal, thyroid tissue and eye lens, which are more radiosensitive than mature tissues (13–15).

Table II demonstrates the tissue weighted factors recommended in ICRP Publication 60 and 103, estimated for newborn, 1-year, 5-year, 10-year, and 15-year male and female individuals (13).

| ORGAN OR TISSUE             | ICR P60 | ICR P103 |
|-----------------------------|---------|----------|
| GONADS                      | 0.2     | 0.08     |
| RED BONE MARROW             | 0.12    | 0.12     |
| LUNG                        | 0.12    | 0.12     |
| COLON                       | 0.12    | 0.12     |
| STOMACH                     | 0.12    | 0.12     |
| BREAST                      | 0.05    | 0.12     |
| BLADDER                     | 0.05    | 0.04     |
| LIVER                       | 0.05    | 0.04     |
| ESOPHAGUS                   | 0.05    | 0.04     |
| THYROID                     | 0.05    | 0.04     |
| SKIN                        | 0.01    | 0.01     |
| BONE SURFACE                | 0.01    | 0.01     |
| BRAIN <sup>A</sup>          |         | 0.01     |
| SALIVAR GLANDS <sup>B</sup> |         | 0.01     |
| REMAINDER                   | 0.05    | 0.12     |
| TOTAL                       | 1       | 1        |

Table 1.1 – Tissue weighting factor published in ICR Publications 60 and 103 (13)

<sup>A</sup> Brain is included in the remainder in ICR P60.

<sup>B</sup> Tissue weighting factor was not given to salivary glands in ICR P60.

The paediatric organs see a higher effective radiation dose due to smaller overall size and cross-sectional area. Lastly, the negative oncologic consequences of radiation have a long latency period. Tiffany J. Zens *et al* (2018) states that children have significantly longer life expectancies than adults. They are more likely to manifest potential radiation-induced cancer. It is estimated that for one in every a thousand CTs performed on a child, there is potential for fatal cancer, which translates to a 0.35% increase in expected lifetime cancer risk (15).

The Radiological Staff is guided by the ALARA principle (As Low As Reasonably Achievable), which encourages the use of a nonionizing imaging modality, if feasible. As MRI does not use of ionizing radiation, allows morphologic, functional, multiphase post-contrast imaging, 3D images, and a set of post-processing features, is a technique equally potential like CT but whose is generally avoided because of the relatively extensive radiation exposure needed to image the same volumes of tissue. Multiphase post-contrast imaging allows improved tissue characterization and lesion detection in most of cases. Also, the ability to perform both arterial and venous-phase post-contrast imaging and organ-specific contrast agents can give a more complete assessment of

normal vascular structures and the adjacent organs (12,16). In addition, MRI provides additional information in many situations due to its better soft-tissue resolution, dynamic imaging capability, and newer techniques such as diffusion-weighted imaging and may be repeated to disease monitoring without any concern (1,6,9,15,17,18).

However, acquiring high-quality abdominal MR images can be challenging in children since, in this population, normal structures are smaller than in adults. Still, it is often forgotten how small they are compared to the average adult. The improved signal-to-noise ratio (SNR) at higher field strength allows the acquisition of thinner slices and improved spatial detail of these structures due to the fact of anatomic structures are higher water components and less discrimination between them or in its interfaces. Another challenge is the children's pulse and respiratory rates that are considerably faster. Children are also unable to hold their breath satisfactorily until they are about 8 years of age. These parameters are significant for cardiac, chest, and abdominal imaging and benefit from the shorter scan times as a result of the improved temporal resolution (8,19).

One of the biggest challenges in children is getting them to cooperate. What is often overlooked is the need for controlled ventilation and breath-holding (BH) to minimize motion artifact in younger children. This involves some inherent risk, requires specialized staff, MR compatible anaesthetic, and monitoring equipment. It is also slow and expensive (8,10,11). Depending on the child's age and conditions, sedation, or GA (deep sedation) can be required for the accomplishment of the MRI scan. Sedation is associated with a lower possibility of diagnostic errors, fewer image quality concerns, and fewer incomplete reports. Compared to sedation, GA is preferred in preterm or at-risk children because its safety and success are predictable, and is also often preferred for post-contrast imaging with BH (20).

Most clinical indications for abdominal imaging in children's are: evaluation of abdominal tumours and lesions, both for diagnosis and differential as well as for preoperative imaging, for assessment of complications and follow-up; liver and bile duct conditions as well as the pancreas; the genito-urinary tract; major abdominal vessels, both in vascular malformations and anomalies such as thrombosis or aneurysm and for pre and post-operative assessment; additional miscellaneous queries such as MRI in post-traumatic or inflammatory complications (21,22).

MRI is the best imaging technique to differentiate active inflammation from fibrosis. Several studies demonstrate that MRI are been progressively used for diagnosis and assessment of disease activity of the small bowel (SB) in children. According to *Manon*

L. W. Ziech (2014), MRI shows sensitivity in children for detecting inflammatory bowel disease ranges from 61% to 92% and specificity from 60% to 92% (23). In Naganuma, M. *et al* (2015), revealed high sensitivity (85%), specificity (78%), and accuracy (83%) for the diagnosis of mucosal healing (24). Athanasios Athanasakos *et al* (2015) describe that for active disease, the sensitivity and specificity of MRI are estimated as 87.5 and 79.3 %, while for fibrosis, the sensitivity and specificity of MRE are 57.1 and 82.1 % (25). An UK study carried out in NHS hospitals by Stuart A Taylor *et al* (2018), showed that MRI is highly accurate for detecting Crohn's Disease (CD), achieving 97% sensitivity for MRI Enterogram (MRE). They also found MRE had significantly higher sensitivity and specificity for SB extent, and higher sensitivity for disease presence (26). In addition, the administration of an oral contrast agent improved the sensitivity and specificity in determining CD lesions (27).

Based on this research problem the following research question emerged: According to the challenges in the paediatric population, it will be effective, or not, the use of sedation and GA to acquire MRE images with enough quality to diagnostic?

In line with this guiding principle and to answer the question above, the objectives of this study are to explore the factors that influence the image quality in MRE and compare them with and without conscious depression appliance.

This report presents a first section where a small introduction to the subject and the importance of this study in the paediatric MRI. Chapter two addresses the basis of the MRE scan, describing the main clinical indications for this exam, the artifacts encounter in abdominal MRI such as the complications and risks of going under a GA procedure. In this same chapter is describe how the referral for a paediatric MRI in the hospital where the study was performed and the preparation and procedures for an MRE. Chapter three comprises the study components: sample, how the data collection was done, the study methodology, and the statistical analysis applied. In chapter four the results of the data collected are presented and summarised. Chapter five includes the discussion of the results analysed in the previous chapter that takes us to chapter six, where a brief conclusion is giving as also the limitations of this study.

## 2 Framework

One of the main considerations when selecting the imaging modality in children is the radiation protection in this concern Magnetic Imaging Resonance (MRI) has become a valuable imaging option in the paediatric abdomen. The challenges in paediatric MRI may be addressed to main tree factors: body composition; specific pathologies or children's behaviour.

The aim is to achieve a diagnostic image quality in the shortest possible time with enough resolution to reliably evaluate the structures in the study. This requires intrinsic knowledge about typical paediatric conditions and their pathophysiology as well as on fundamental MRI principles, and good interaction between the Radiologist and the Radiographer. The use of and need for intravenous contrast media needs to be reassessed for every individual investigation because of various risks such as gadolinium-associated nephrogenic systemic fibrosis (NSF) and the potential long-term sequelae of gadolinium deposit in the child's bone marrow (28).

Computed Tomography (CT) is an alternative approach to assess traumatic and non-traumatic abdominal and pelvic pathology in children. However, the potential of cancer induction, overexposures, or unjustified use of imaging or enhanced radiation risk, makes this modality questionable for paediatric assessment. Even with all the efforts and focus on reduction in radiation dose per CT exam, there remains a lack of information characterizing the patients who receive the highest cumulative doses from recurring CT exams. Approximately one-third of children who have undergone CT scans have already had at least three different scans in their lifetime added to their cumulative dose (29,30).

Even though the risk of experiencing radiation-induced cancer for a given child is small, the concern is related to the rise in the use of radiation for diagnostic purposes. The rapidly dividing cells in children are more radiosensitive than those of adults. Besides, children have a longer lifetime in which radiation-related cancers can become evident, and the current conservative theory is that the cancer risk is cumulative over a lifetime. This means that each x-ray examination contributes to the lifetime exposure and therefore increases the risk of inducing fatal cancer (14,30). Evidence suggested that irradiating the pelvis may be responsible for the consequent genetic and somatic malignancies. Vahid, K. *et al* (2017) says that it has been estimated that a 1-year-old patient is ten or fifteen times more likely to develop radiation-induced malignancy than a 50-year-old patient followed to exposure to an identical dose (31). There have been a lot of efforts by the manufacturers and even the institutions to lower the dose in the CT exams, but there are limits on lowering the radiation dose. One example is the poor

image quality that can provide from lowering the dose that can lead to a missing diagnosis (30).

In the case of chronic diseases, imaging modalities that do not require the use of ionizing radiation should be considered whenever possible to keep the cumulative lifetime radiation dose as low as possible. For example, MRI Enterogram (MRE) should be considered in inflammatory bowel disease (IBD) as an alternative diagnostic method (30,31).

In the detection of abdominal disease in young children, MR images present unique challenges since younger patients have less abdominal fat to serve as a natural contrast mechanism between anatomic structures and plans interfaces to discriminate organs. Relative to body weight, the water content of the extracellular space is much greater in early life. In fact, abdominal organs in children have higher water content than in adults, and in the other hand the bone marrow of infants is primarily hematopoietic, contains abundant water, and is thus difficult to differentiate from infiltrated marrow. The main indications for abdominal and pelvic MR imaging in children are congenital disorders, tumours, and infections (28,32).

## 2.1 Small bowel pathology

Inflammatory bowel diseases (IBD) can be divided into 2 disease types Crohn's Disease (CD) and ulcerative colitis (UC), which differ mainly in the histological features and bowel disease distribution as also involves genetic factors, immune system dysregulation, and environmental factors. UC involves primarily the colon, and the symptoms include continuous or repeated blood in the stool and diarrhoea. CD may involve the entire gastrointestinal tract including the small intestine, colon, oesophagus, and stomach. Perianal lesions are frequently observed in patients with CD sometimes associated with the fistula tract, where MRI has a very specific detection. UC is characterized by continuous colonic mucosal inflammation. Because inflammation in CD involves the entire gastrointestinal tract and the small intestine, assessment of small intestinal lesions in CD is critical. As a result, the CD is more typically characterized by long-term frequent symptomatic recurrence over the lifetime of the patient (24,33). There is a high risk of perianal fistula formation in the CD that ranges from 30–50%, with the presence of a fistula leading to significant morbidity due to cutaneous drainage or perianal abscess formation. The soft-tissue contrast of MRI provides detailed anatomic delineation of the anal sphincter complex (33). Approximately 1.6 million Europeans are affected with CD and 2.1 million with UC, of whom 25% of patients first present during childhood or adolescence as describe in Athanasakos, A. *et al* (2015) study. Paediatric IBD is

characterized by different atypical phenotypes from the adult-onset disease because of a different genetic basis and age-related regulation of the inflammatory process (25).

## 2.2 Techniques in paediatric MRI

Abdominal imaging requires that the patient cooperates through breathing instructions and voluntary immobilization. However, patients that need to perform this type of exam can experience various emotions such as fear, anxiety, and the uncontrolled sensation of escape. In children, anxiety and distress are common feelings in MRI scans. This is due to different reasons like the equipment design, the confined space, the need to stay immobile during the session, afraid of the unknown and the need to do it by themselves as well for being a medical procedure. When a child is not capable to cooperate, they tend to move, and this is going to generate movement artifacts. In this situation the Radiographer needs to spend more time repeating the sequences to obtain a diagnostic scan because the children are most unlikely to tolerate an MRI being awake. In certain cases, many repetitions are not a good solution because the children time after time became more excited and less cooperate (1,6,11,17). So, the final result is to spend more time, the children become more nervous, and the images acquired are less diagnostic quality. This includes not being capable of following instructions, keeping still inside the scanner during a long period, or manage the acoustic noise associated with the MRI scanner. In children between 6 months to 6 years, sedation or general anaesthetic (GA) is commonly required in a way to obtain diagnostic images (7,17). However, these procedures have secondary effects, and they should be used judiciously. The *American Academy of Pediatrics* emphasizes that the role of sedation is reducing discomfort, stress, and control the child anxiety control has the MRI equipment is close, the time of the scan can reach 45 minutes or longer and the image quality can be degraded by the patient movement (1).

Maxim Zaitsev *et al* (2015) states that for young children, training with a mock MRI is useful to avoid motion by reducing anxiety through distraction and compliance strategies. However, this solution is not always available and is not cost-effective for some centers. In younger children, like neonates and infants, imaging can be performed timed after feeding to take advantage of sleeping that usually follow it. But in most cases, these methods are not always efficient. Sedation or GA is often used when imaging young children. Sedation is not always effective and in approximately 12% of cases, there is an occurrence of motion artifacts increasing the prevalence of failures in older children. GA is more trustworthy, with a lower incidence of motion artifacts but is associated with much greater costs, more serious side effects, and greater risks to health (34). For abdomen

imaging, the breathing artifact is quite frequent so there is the need to suppress it. The most effective solution is to perform the sequences with breath-holding (BH). Consequently this, limits the scan duration (10 to 20 seconds for the BH). This time limitation can sometimes restrict the image resolution and length scan for all structure's coverage. There have been software and hardware attempts to overcome this need such as respiratory-triggering techniques or k-space sampling methods. Respiratory triggering can be performed with bellows or navigator pulses and is used to synchronize image acquisition to a constant phase of the respiratory cycle. Opposite, the navigator-triggered technique, that uses the navigator echoes to monitor respiratory motion, demonstrates to be more reliable than bellows in the younger child and does not have the risk of interruption because of dislocation of the bellows (32,34–36). Regarding k-space sampling methods, the purpose is to use fast sequences such that good images are achieved without respiratory motion artifacts. Rotated overlapping parallel lines with enhanced reconstruction (Periodically Rotated Overlapping Parallel Lines with Enhanced Reconstruction - PROPELLER) has been widely applied in clinical MRI (also known BLADE – Siemens terminology). These method uses a novel approach to acquire a number of blades that consist of parallel k-space lines that are collected around the center of the k-space and fill the k-space using these radially oriented blades, with resultant oversampling of its center. The major advantage is that it uses inherent data to correct for motion due to in-plane rotation and translation. These sequences are found to be a great alternative to conventional turbo spin-echo (TSE) with a respiratory triggering for abdominal MRI in children (32,35,37).

Fast T2-weighted (T2W) imaging is usually performed using single-shot fast spin-echo (FSE) sequences that are motion insensitive because of their rapid spin echo-train that enables acquisition of an entire image in one radiofrequency excitation pulse. Partial Fourier reconstruction techniques such as half-Fourier Rapid Acquisition with Relaxation Enhancement (RARE) can be allied to further reduce scan time. These sequences allow the entire abdomen and pelvis to be imaged within a single BH acquisition and they are routinely used in younger children with no significant degradation of image quality. The necessarily long echo-train length (ETL) associated with the single-shot technique, decreases SNR and tissue contrast. The pathology can be missed but the interfaces between anatomical structures and the differentiation between fluid and soft tissue are preserved, permitting reliable evaluation of fluid-filled structures, bowel wall oedema, and extraluminal fluid collections (32,36).

Balanced steady-state free precession (bSSFP) acquisitions are fast gradient echo (GRE) sequences. They can provide both T1-weighted (T1W) and T2W contrast and

they have an elevated sensitivity to flow and opposed-phase contrast that has become very useful for fast imaging of the abdomen. They allow imaging of the entire abdomen within 10 to 20 seconds and acquires nearly motion-free images even in free-breathing children, although respiratory triggering is also available (32,36).

An additional artifact reduction approach can be accomplished by reducing the signal intensity of moving structures such as the abdominal wall or the diaphragm. Common applications include using fat-suppression techniques to null signal from the anterior abdominal wall fat and placing saturation bands over the dome of the diaphragm or vascular structures (32,36).

## **2.3 MRI abdominal artifacts**

Artifact is defined as an artificial element showing in the image that is not present in the original body. It is imperative to identify these artifacts since they can mask or mimic a pathology and they can lead to erroneous diagnosis causing serious after-effects on patient's health and outcomes (38,39).

One of the MRI conflicts has been sensitivity to patient's motion, particularly in children. The acquisition time required is far longer than the timescale of most types of physiological motion such as involuntary movements, cardiac and respiratory motion, gastrointestinal peristalsis, vessel pulsation, blood, and cerebrospinal fluid (CSF) flow. The effects of motion include blurring and ghosting in the image. The appearance of motion artifacts in an image is a result of a complicated interaction between the image structure, the type of motion, the specifics of the MRI pulse sequence, and the k-space acquisition strategy (34,36,37). The most common artifacts may appear in paediatric MR images from abdominal and pelvis studies are described below.

### **2.3.1 B1 inhomogeneity**

B1 inhomogeneity produces regions of reduced signal in the center of the imaged object. This effect is caused by a combination of variable and reduced RF penetration depth as the magnetic field strength increases and dielectric tissue properties cause resonance phenomena that appear as standing waves when half the wavelength is in the order of the object size. This is an important artifact in 3T equipment, is unpredictable, and depends on the body shape and organ size. It is less of a problem in smaller children, as the tissue depth for RF penetration is less and the organ size smaller. It can affect abdominal MR images of older children. Appropriate shimming is helpful to move these dark bands away from the region of interest. The primary solution of field inhomogeneity is the setting of the shim coils and increasing the spatial resolution (8,40).

### 2.3.2 Aliasing or phase wrapping artifacts

Aliasing artifacts occur when the anatomical structures located outside the field of view (FOV) are mapped at the opposite end of the image (38,41). This is seen most frequently in the phase-encoding direction. These parts are wrapped around and spatially miss-mapped to the opposite side of the image. This artifact can be avoided by increasing the FOV, the frequency-and phase-encoding directions can be switched as there is no wrap-around phenomena in the frequency-encoding direction, special algorithms prevent phase wrapping by oversampling in k-space, surface coils can be arranged in such a way that structures which otherwise might wrap around come to lie outside the sensitive range of the receive coil and thus do not appear in the image (38,40,41).

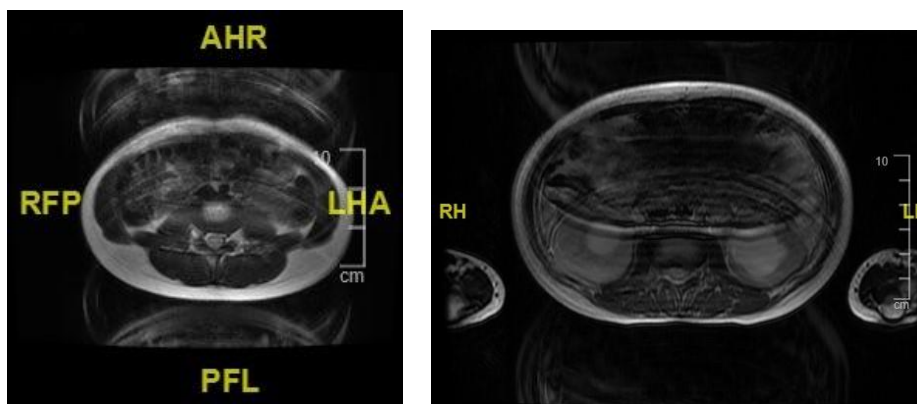


Figure 2.1 – Axial T2-weighted images in a paediatric abdominal imaging. Aliasing artifact can be observed.  
Source: UHL

### 2.3.3 Chemical shift artifact

Chemical shift artifacts appear as dark or bright bands at the lipid-water interface and are seen especially in case of fluid-filled structures surrounded by fat. Inherent differences in the precessional rates of fat and water in an applied magnetic field result in spatial shifts in the frequency-encoding direction. This can be minimized by enlarging the sampling bandwidth, applying a frequency-selective pre-saturation pulse for the adipose tissue, increasing the voxel size, choosing an echo time so that water and fat are in phase and switching phase/frequency encoding direction. Dual-echo Dixon technique, a chemical shift-encoding technique which allows separating water and fat and ensures an excellent fat suppression (FS) with the assessment of the spatial distribution of fat, can help recognize fat–water interfaces, which generate artifacts (32,38,41).

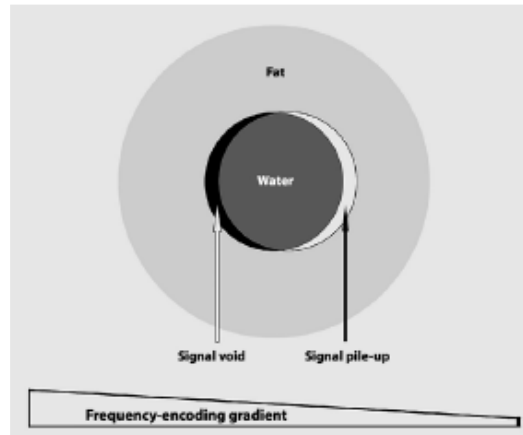


Figure 1.2 – Demonstration of the chemical shift artifact at a fat-water interface (34).

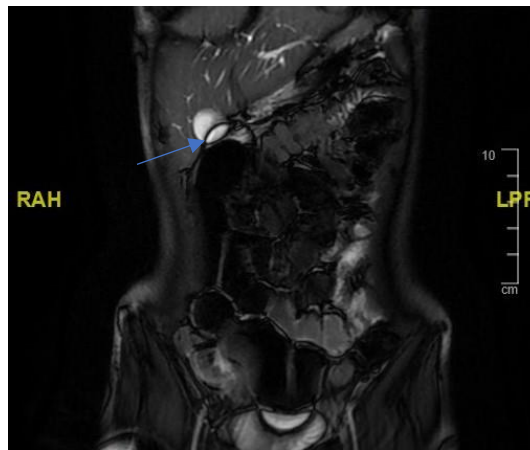


Figure 2.2 – Coronal FIESTA FS cine stack in a paediatric MRE. It can be observed in the image a dark line (blue arrow) that characterizes a chemical shift artifact. Source: UHL

### 2.3.4 Patient-related artifacts

Two types of motion artifacts are commonly encountered in routine MR imaging: artifacts caused by breathing, peristalsis, or the beating heart (respiratory and cardiac motion artifacts) or caused by pulsatile blood flow or circulation of CSF (pulsation artifacts) (32,38,41).

Motion artifacts caused by breathing, cardiac movement, patient movement, can create either ghost images or diffuse image blurring. They can be reduced by patient immobilization, cardiac/respiratory gating, saturation bands, signal averaging, swapping phase- and frequency-encoding directions, the intestinal peristalsis can reduce the administration of a spasmolytic agent. Also, the use of echo-planar imaging (EPI) or the use of fast GRE sequences for breath-held volume imaging (9,32,38,40,42).

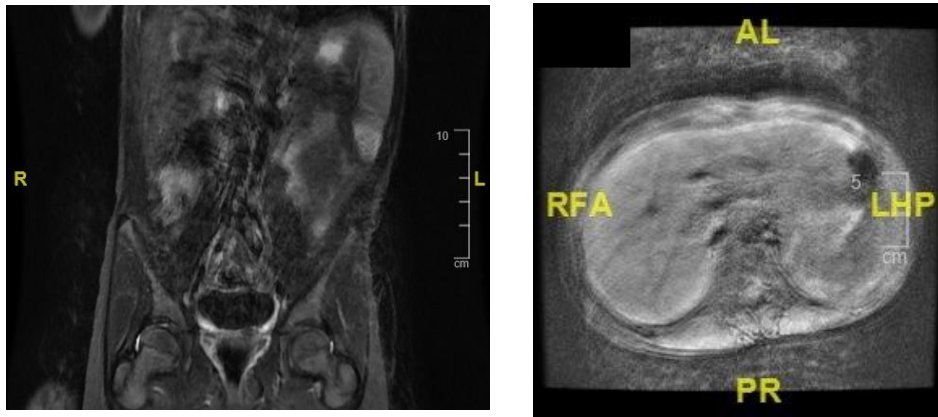


Figure 2.3 – Coronal STIR (left image) and Axial T1 FS (right image) showing movement and breathing artifacts in paediatric abdominal scans. Source: UHL

Pulsation artifacts are caused by flowing blood as well as the flow of CSF and occur in the phase-encoding direction. These artifacts are generated from the spins moving along a magnetic field gradient (slice-selection, phase-encoding, or frequency-encoding gradient) to experience a phase shift. As a result, anatomy moving during the phase-sampling interval is assigned a wrong phase value and depicted in a different place in the image. These can be reduced by reduction of phase shifts with flow compensation, suppression of the blood signal with saturation pulses parallel to the slices, and electrocardiogram triggering (9,32,38,40,42).

Other strategies beyond the appliance of techniques should carry out like immobilizations relaxation or distraction methods.

Varied studies indicated that previous MRI training methods may assist in obtaining high-quality images with no motion or slight motion for diagnosis. These methodologies, such as, booklets, audio, video, MRI model, and behavioural interventions, can make the child familiar with and interested in scanning process, increasing the acquirement of high-quality images, and successive completion of the exam (4).

Runge S. B. *et al* (2018) developed a prospective clinical study, in which a multi-faceted, child-friendly concept combining an interactive app was created, dedicated Paediatric Radiographers, and the use a children's lounge and a child-friendly environment in the MRI room that gave a suitable environment for children. This should be age-appropriate and may include elements like preparation, motivation, child-friendly communication, and positive distraction. This study showed that 95% (39 in 41) of children aged 4–6 completed a diagnostic MRI without GA, maintaining the image quality was maintained, and the setup was cost-effective (43).

Mathur A. *et al* (2016) used music therapy as a support for MRI exams. The outcomes such as patient's perception of pain, use of coping strategies and adaptive or maladaptive behaviours were evaluated within the moment and applied to inform any alterations in the music therapy intervention. The results demonstrated that 12 years and younger who were scheduled to receive parenteral sedation for the MRI studies, showed that a lower percentage of children who received some form of music therapy did not required the use of sedation, in comparison to those who did not have an intervention (44).

A retrospective review presented by Mastro K. A. *et al* (2019), revealed that an intervention based in patient- and family-centered preparation of the child with no anaesthesia given, that used a structured methodology to create an individualized patient-centered plan to prepare the child for MRI, led to successful completion of the exam with 96.8% of the MR images being acceptable or of better quality and deemed interpretable by the Radiologist. This approach is based on the personal knowledge of the child/family for the development of a personalized preparation, maximize the true potential of the child in completing positively the exam without the use of sedation. He also stated that even though, patients that are sedated have a better quality of scan image, this method remains a viable option to sedation (45).

## 2.4 General anaesthetic or sedation – complications and risks

For MRI scans, children are most of the time sedated or submitted to a general anaesthetic (GA) procedure in a way to reduce their anxiety and assure that the image acquisition has quality to diagnostic and is free of movement artifacts. However, these two methods have related costs and risks. Some preliminary studies show the association between premature exposure to GA procedure and the learning difficulties or behavioural disorders (1,5,46).

Sedation and GA have the purpose to generate a state of relaxation, immobility, analgesic, and amnesia during the MRI scan, minimizing the toxic risks associate. The level of sedation required for an MRI exam in a young child is typically profound sedation, losing consciousness with preservation of the stimulus in response to pain. This is mainly used in toddlers or young children that cannot stay still. In addition, the regular respiratory pattern produces during sedation results in higher quality in the respiratory trigger. A GA procedure, define as loss of consciousness without preserving the stimulus in response to pain, requires intubation (1,10,17,47,48).

The ideal sedation agent for use in paediatric imaging as to be easy to administer, fast-acting, predictable, rapidly reversible, and well-tolerated. The most common classes of medication used for imaging procedures have been benzodiazepines (midazolam), opioid analgesics, intravenous anaesthetics such as propofol and ketamine, inhalational anaesthetics like sevoflurane, selective alpha-2 agonists (dexmedetomidine), and hypnotics, for example the chloral hydrate (49).

The medication used to induce sedation normally tends to be weaker and with a large safety margin, in which most of the cases do not work, where the medications for the anaesthetic stage are more powerful but of short action and with a limited safety. The chloral hydrate or midazolam are the most common drugs used in paediatric sedation and with a lower rate of side effects but with a higher rate of non-diagnostic exams. One of the concerns with sedation is over-sedation that in young toddlers can be manifest by desaturations or apnoea (17,49).

GA is thus required for many of those between 1 and 7 years old, and some older children with learning difficulties or claustrophobia. With this procedure, the patient breathes spontaneously but protective reflexes may be lost and the ability to maintain an airway is not assured, been necessary the intubation if the patient. The potential complications include hypoventilation, apnoea, airway obstruction, aspiration, hypotension, and bradycardia. For example, has been recorded with the use of dexmedetomidine complications like bradycardia and myocardium hypotension, use of propofol and

ketamine related with respiratory depression, hypertension, and hallucinations. Luckily, the number of events associated with early hazards was reported under 0.4% with hypoxemia and aspiration the most common complications (1,17,46).

Preconditions for sedation and GA are almost the same: fasting, intravenous access, vital signs monitoring, emergency equipment and a physician experience in using the technical equipment and trained in paediatric airway management. The only difference is that for a GA procedure, an anaesthetic team is required to assist with the case and monitor the patient during the examination. Is required a review on the medication prescriptions and administration of the same, as monitoring the patient during and after the MRI scan. In each session, depending how long the exam requires or the anatomical area studied, more than one child is booked to have the exam in the same day, being able to use the resources dispended. However, if any complication emerges, the time of monitorization needs to be extended. This incident can restrict the rest of the patient list has you can only proceed when the first patient is stabilized (2,17,50–52).

The need for GA in patients can generate a significant operational disfunction and administrative burden in the imaging departments by evaluating how long it takes to sedate a patient, the requirement of additional monitoring, and the continuous risk of respiratory depression. These factors can affect the patient in a negative approach, increasing the costs, and also have negative impact within the staff but they required to work as a team and be versatile in a way to support and improve the experience of the patient (17,53).

A written and informed consent should always be taken with the parents or guardians where is communicated what the procedure involves, the proposed sedation and the alternatives to sedation, as well the risks and benefits. In an urgent case that the child did not fast, the risks of aspiration during the chosen sedation technique should be weighed against the consequences of delay in the procedure. Intravenous access may be difficult in children and, whenever delivery of intravenous drugs and fluids are unnecessary, or not likely, it may be omitted. The clinical team involved should understand and be competent in the technique being used. This should include, beyond imaging, the pharmacology, applied physiology, patient assessment, monitoring, and care in recovery. It must be able to recognize and manage any complications. The anaesthesiologist should have operating department practitioner (ODP) assisting with the case. The anaesthesia should be induced in a dedicated anaesthetic room adjacent to the MRI scanner but outside the control area. This provides an area in which standard anaesthetic and resuscitation equipment can be stored and used. The location should

be with easy access such that anaesthetized patients can be straightforwardly and rapidly transferred into the scanner and rapidly retrieved in an emergency. The transfer of the patients into the scanning room must be done on an MRI safe non-ferrous trolley. The airway of the patient who goes into the magnet is completely inaccessible. So, the anaesthetist must be satisfied with the security of the airway before the beginning of the scan. All monitoring equipment used in the MRI scanner should be designed for use in this environment and is typically designated MR safe or lower conditional. It is endorsing that all monitoring equipment should be placed in the control room outside the magnet room. MRI compatible anaesthetic machines and ventilators can be located adjacent to the magnet bore, minimizing the length of the breathing system and allowing a safe delivery of volatile anaesthesia. A minimum standard of monitoring with continuous oxygen saturation by pulse oximetry and heart rate may be needed for minimal sedation. When in conscious or deep sedation techniques, ECG, arterial pressure, and capnography is mandatory. Patient monitoring should be documented during all the scan as well after the procedure. Any nausea, vomiting, and pain should be adequately managed before sending the patient home (54,55).

## **2.5 Paediatric MRI at University Hospitals of Leicester**

In the University Hospitals of Leicester (UHL), with paediatric patients, when an MRI referral is generated, the clinicians are the ones to decide if, depending in the child age, is required or not to perform the scan under sedation or GA, assessing the child's condition (if any breathing problems or cardiac surgeries). Normally, sedation is only used in neonates or children under 1 year old. Above 1 year, if a GA procedure is required, the clinician needs to discuss and have signed a consent with the parents or guardians. Both the consent and the referral form need to be delivered in the MRI department. After these have been uploaded into the system, the exam is accepted by the Paediatric Radiologist and an emergency code is given depending how urgent the exam need to be done. An appointment for the MRI and the GA procedure are given depending on if a slot is available and if the anaesthetic team is also available to assist the case. A pre-assessment is done on the day by the anaesthetist that can decide if his safe or not for the child to go under GA. A play specialist is always involved in the GA process and escorts the patient when he comes to his MRI scan.

At the department, in the back of the control area, there is a dedicated anaesthetic room that is used by the anaesthetic team to intubate the child. In that room, there is a ventilator that is not MRI compatible. Once intubated, the child is transferred to the MRI room with an MRI compatible trolley and already connected to the wireless monitor, MRI

compatible, to monitor the patient vital signs such heartbeat and oxygen saturation. Inside the MRI room, there is an MRI safe ventilator, that supports the patient respiration through the exam.

Sometimes, the clinicians as well the parents, prefer that the child attempts the exam without going under GA. If the child cannot tolerate the scan, the request needs to be discussed with the Radiologist and decide if the images acquired are enough for the diagnosis or if the child needs to repeat the scan under GA.

## 2.6 MR Enterogram

MR Enterogram (MRE) is a non-invasive imaging technique that allows the study of the small bowel (SB). The inflammatory bowel disease (IBD) requires repeated study for disease assessment and therapeutic monitorization, so the MRE is considered a primary imaging modality for paediatric and young adult population due to the absence of ionizing radiation. This technique has been reported to be a useful modality for the evaluation of luminal inflammation and extraintestinal complications in the SB. MRE is particularly valuable for detecting transmural inflammation, stenosis, and extraintestinal lesions including abscesses and fistulas, as well as extraluminal imaging features of disease such as mesenteric lymphadenopathy, ascites, and fibrofatty proliferative changes (24,25,33,56). Another future role for MRE in CD is the detection of mural fibrosis. Fibrosis is considered a late-phase irreversible result of chronic bowel wall inflammation leading to collagen fiber deposition in the submucosal and serosal layers of the bowel wall. Mural fibrosis frequently leads to luminal narrowing associated with proximal bowel obstruction and, unlike acute inflammatory strictures; fibrotic strictures usually require surgical resection to alleviate the associated obstruction. It is important to differentiate between active and inactive inflammation, with the presence of active disease to be considered an indication to initiate or modify medical therapy (33,57).

Dominik Bettenworth *et al* (2011) describe that in paediatric patients with CD, 20% of patients are found to have strictures at diagnosis, increasing to 40% of patients by ten years. In opposition, a considerable proportion of up to 20% of patients with SB stenoses in CD are asymptomatic (57).

The American College of Radiology on ACR–SAR–SPR PRACTICE PARAMETER FOR THE PERFORMANCE OF MAGNETIC RESONANCE (MR) ENTEROGRAPHY paper, defines that bowel preparation is required to improve the diagnostic performance of MRE study. The goal of bowel preparation is to achieve maximal distension of bowel loops to improve visibility of luminal disease; reduce bowel peristaltic activity to improve the

diagnostic quality of motion-sensitive MR sequences and displace air within bowel loops that can cause susceptibility artifact on GRE sequences as described (Figure 2.5).

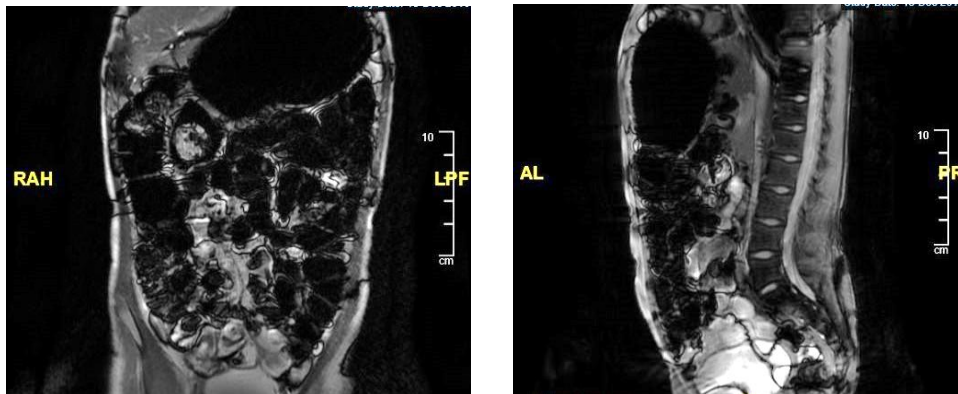


Figure 2.5 – Coronal (left image) and Sagittal (right image) FIESTA FS sequences from the same patient. These show a not good preparation of the patient has the stomach and the bowel are full of air and the images become non diagnostic. Source: UHL

For exam preparation, some requirements are needed. Oral contrast is administered to patients before MRE to improve small-bowel distension. Patients may be asked to fast for four to six hours before the examination to improve compliance with the ingestion of enteric contrast preparations. Oral contrast agents should provide some osmotic effect to prevent water absorption by the bowel and a viscosity agent to promote distension. In addition, the generally favoured contrast agents demonstrate bright signal on T2W images and dark signal on T1W images, to achieve maximum contrast with the bowel wall, especially on T1W postcontrast sequences – the bowel wall will enhance, and the distended lumen will remain low signal. A defined time delay from the administration of oral contrast to imaging allows for the adequate distal passage of contrast prior to image acquisition. Rectal contrast may assist in visualization of the ileocecal junction (56). Oral contrast agents are classified according to the action on the signal intensity of bowel lumen: positive, negative, and biphasic agents. The positive agents show high signal intensity on both T1W and T2W images. However, as the T1W of tissues is much higher than the T2W, the tissues that absorb these agents become bright on T1W images. Naturally prepared fruit juices of medlar and blueberry as also green tea, have been studied as MRI contrast agents for several years. Negative contrast agents use the paramagnetic properties of heavy metal ions, particularly manganese, barium, and gadolinium, to reduce the signal of the intestinal lumen, by shortening the T2 relaxation time, on both T1W and T2W images, producing a “black lumen” effect. Barium sulfate suspensions can be used as oral contrast agent. Pineapple is a fruit with the highest manganese concentration and is widely used as a natural negative oral contrast for the

cholangiopancreatography in a way to suppress signal from the adjacent gastric and duodenal fluids for a proper evaluation of the bile and pancreatic ducts. Biphasic contrast agents are water-based agents that contain non-absorbable additives to create a hyperosmolar solution (polyethylene glycol, sorbitol, lactulose, mannitol solutions) that produces a negative effect on T1W and a positive effect on T2W images (“water-like” effect), as showed in Figure 2.6 (right image). This low luminal signal intensity on T2W images include better visualization of bowel wall oedema and mucosal enhancement as well as discrimination of intraluminal and extraluminal fluid, while positive luminal signal intensity is often favoured for the detection of bowel wall thickening (27,33,41,58,59). Biphasic contrast agents are most employed oral contrast agents due to their favourable signal characteristics for detecting bowel pathology (60).

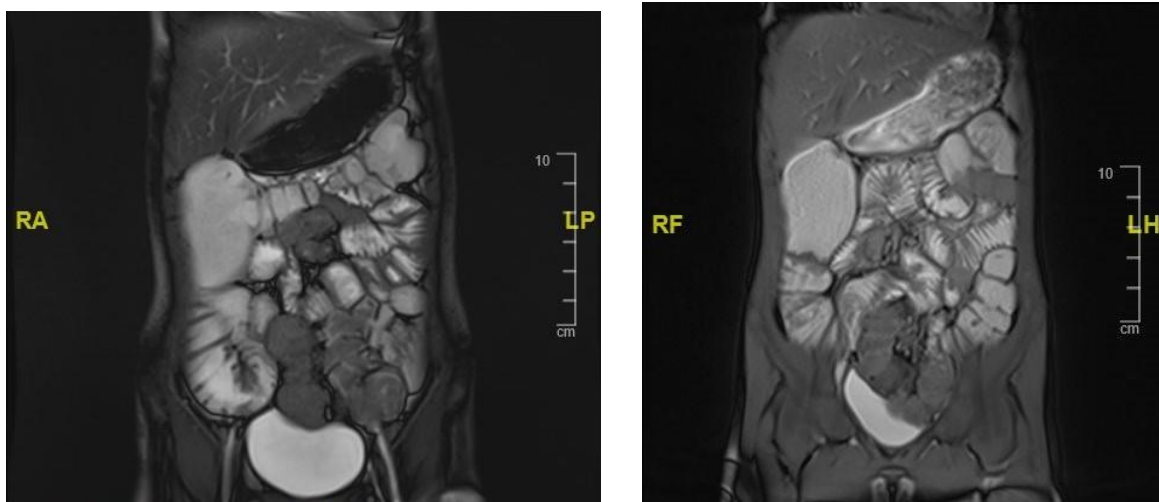


Figure 2.6 – Coronal FIESTA FS plane from a cine stack (left image) and True FISP (right image) sequences from two different MRE with oral contrast in paediatric patients. The bowel demonstrates a good distension and wall enhancement. Source: UHL

Cinematic MR images can be obtained to examine bowel peristalsis. The cine sequence is used to identify segments of abnormal bowel motility, defined as zones of abnormally increased or decreased peristaltic motion compared with adjacent bowel. The addition of the cine sequence led to the detection of an increased number of abnormal bowel segments compared with static MRE images alone. Also, dynamic post-contrast images can be obtained to assess the time course of bowel enhancement. Contrary to CT, MRI provides superior soft-tissue contrast in the absence of intravenous contrast which is valuable for detecting mesenteric inflammatory changes and bowel wall oedema (25,33,57). Both lumen and wall of viscera are well represented as presented in Figure 2.7 (left image).

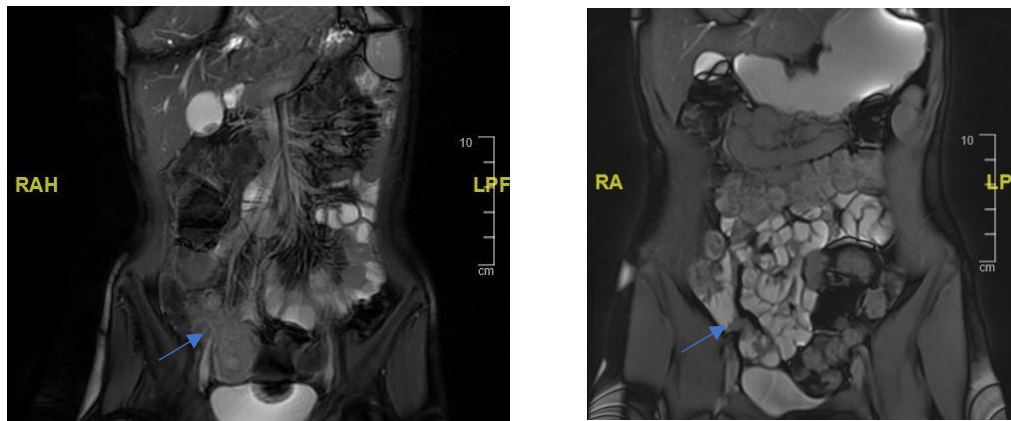


Figure 2.7 – Coronal FIESTA FS from a cine stack sequence (left image) and coronal True FISP sequence (right image) from two different paediatric MRE. In the image it can be observed the inflammation of the terminal ileum (arrows). Source: UHL

Acutely inflamed SB segments in CD patients demonstrate increased perfusion and restricted diffusion. Diffusion-weighted imaging (DWI) and dynamic contrast-enhanced (DCE) sequences are both promising techniques for the detection of active SB inflammation. Reactively enlarged (>5 millimetres in short axis) adjacent mesenteric nodes are often shown in contrast enhancement sequences and high signal on DWI. DWI sequences with high b-values open new horizons in the detection and quantification of bowel wall inflammation. Also, T1W DCE sequences can demonstrate early intense mucosal enhancement followed by progressive transmural enhancement. This layered wall morphology has been attributed to exacerbation of mucosal inflammation in chronic disease, while homogeneous enhancement is more common in newly diagnosed CD (25,27). Other features of MRI sequences in the bowel evaluation are through T2W fat-suppressed images that show increase wall thickening (greater than 3 millimetres) in the abnormal bowel wall and adjacent mesentery. Ulcers and fistulas are best seen on fast imaging with steady-state free precession (SSFP) sequences that reveal avid contrast enhancement (25).

## 2.7 MR Enterogram at University Hospitals of Leicester

There are three scanners in the Leicester Royal Infirmary. One 3 Tesla (T) Discovery by GE and 1.5T Optima also by GE and 1.5T Magnetom Aera by Siemens that is placed outside of the department, in a static unit. Abdominal scans are performed in both higher and lower magnetic fields but even though, the increased signal that the 3T presents have indisputable advantages, due to longer T1 relaxation times, the effect on T2 and T2\*, and the greater chemical shift effect, can result in noticeable artifacts. Also in the 3T scanner, scan times can be longer compared to the 1.5T, and in the presence of fluids, a dielectric effect can compromise the image quality (8,9).

There are three scanners in the department. One 3T Discovery by GE and 1.5T Optima also by GE and 1.5T Magnetom Aera by Siemens. Normally, the MRE scans are performed in the 1.5T scanners.

The GE Discovery MR750w is a full 3.0T magnet with 70 centimeters (cm) bore, that works to generate an extraordinary image quality without compromising the patient comfort on their scan experience. Beyond the widened bore and soft, flexible coils, the table surface was re-designed to help alleviate pressure points for a more relaxing exam. Provides an ergonomically-friendly interface that mimics the same consumer-designed devices that the Radiographer uses every day (61).

The Optima MR450w scanner, with a wide bore, delivers both uncompromised image quality and high productivity, with an expansive 50 cm field of view (FOV). With a 1.5T field strength, 70 cm bore diameter and large FOV, makes MRI scans more accessible for patients who need them. Delivers exquisite image quality to aid in the diagnosis. Allows a better patient positioning autonomy and access to interventional procedures. Such techniques offer new approaches to higher patient care, offering a more comfortable experience for the patients, especially larger individuals, children, and those suffering from claustrophobia. Also, with a higher-generation of clinical applications, it helps on the reducing of the exam time, improving patient security features result in a cooler, quieter experience helping the Radiographer when, for example, scanning children, as one of the main difficulties is getting them to keep still for a certain period in a way to obtain a diagnostic image (62). With these improvements, is possible to obtain a good image, reducing the tense experience of the child.

The Magnetom Aera, the second generation of Siemens with 70 cm open bore system, provides a sophisticated response to challenges. Helps to deliver excellent quality care constantly, regardless of the patient sizes, shapes and conditions or clinical question. The ultra-short magnet (145 cm) allows many studies to be completed with the patient's

head outside the bore. In addition, the patient-friendly lightweight coil design and the illumination allows the patient to relax during their exam. Also, with an advanced noise reduction technology implemented (70% reduction in sound pressure level), increases patient comfort, cooperation, and satisfaction, without compromising the standards of high quality and efficient imaging. (63).

The acquisition protocol parameters applied in this study are shown in table 2.1 for GE Discovery, 2.2 for GE Optima and table 2.3 for the Siemens Aera scanner.

Table 2.1 - Enterogram protocol for GE Discovery scanner.

| PARAMETERS<br>SEQUENCES | SLICE<br>THICKNESS | SPACING | FREQUENCY<br>FOV | PHASE<br>FOV | MATRIX  | TR     | TE  | NEX | TOTAL<br>SEQUENCE<br>TIME |
|-------------------------|--------------------|---------|------------------|--------------|---------|--------|-----|-----|---------------------------|
| FIESTA SAG              | 7.0                | 1.0     | 32.0             | 0.90         | 224x320 | 4.3    | 1.0 | 1   | 22 SEC                    |
| FIESTA FS SAG           | 7.0                | 1.0     | 32.0             | 0.80         | 224x320 | 4.3    | 1.0 | 1   | 25 SEC                    |
| FIESTA CORONAL          | 5.0                | 1.0     | 32.0             | 1.00         | 224x320 | 4.5    | 1.0 | 1   | 26 SEC                    |
| FIESTA FS<br>CORONAL    | 5.0                | 1.0     | 32.0             | 1.00         | 224x320 | 4.8    | 1.0 | 1   | 32 SEC                    |
| FIESTA AXIAL            | 6.0                | 1.0     | 32.0             | 0.80         | 224x256 | 4.3    | 1.0 | 1   | 28 SEC                    |
| FIESTA FS AXIAL         | 6.0                | 1.0     | 32.0             | 0.80         | 224x256 | 4.3    | 1.0 | 1   | 35 SEC                    |
| DWI                     | 5.0                | 1.0     | 40.0             | 1.00         | 92x128  | 2600.0 | 1.0 |     | 3.49 MIN                  |

Sequences parameters used for an MRE scan in the GE scanner (3T). FOV – Field of view; TR – Repetition Time, TE – Echo Time; NEX – Number of excitations; SEC – seconds; MIN – minutes.

Table 2.2 - Enterogram protocol for the GE Optima scanner.

| PARAMETERS<br>SEQUENCES | SLICE<br>THICKNESS | SPACING | FREQUENCY<br>FOV | PHASE<br>FOV | MATRIX  | TR     | TE  | NEX | TOTAL<br>SEQUENCE<br>TIME |
|-------------------------|--------------------|---------|------------------|--------------|---------|--------|-----|-----|---------------------------|
| FIESTA SAG              | 7.0                | 1.0     | 38.0             | 0.90         | 224x320 | 3.7    | 1.0 | 1   | 19 SEC                    |
| FIESTA FS SAG           | 7.0                | 1.0     | 38.0             | 0.80         | 224x320 | 3.7    | 1.0 | 1   | 21 SEC                    |
| FIESTA CORONAL          | 7.0                | 1.0     | 40.0             | 1.00         | 224x320 | 3.7    | 1.0 | 1   | 16 SEC                    |
| FIESTA FS<br>CORONAL    | 7.0                | 1.0     | 40.0             | 1.00         | 224x320 | 3.7    | 1.0 | 1   | 19 SEC                    |
| FIESTA AXIAL            | 6.0                | 1.0     | 36.0             | 0.80         | 224x288 | 4.1    | 1.0 | 1   | 31 SEC                    |
| FIESTA FS AXIAL         | 6.0                | 1.0     | 36.0             | 0.80         | 224x288 | 4.1    | 1.0 | 1   | 38 SEC                    |
| DWI                     | 5.0                | 1.0     | 44.0             | 1.00         | 92x128  | 2000.0 | 1.0 |     | 5.40 MIN                  |

Sequences parameters used for an MRE scan in the GE Optima scanner (1.5T). FOV – Field of view; TR – Repetition Time, TE – Echo Time; NEX – Number of excitations; SEC – seconds; MIN – minutes.

Table 2.3 – Protocol sequences for Siemens Aera scanner.

| PARAMETERS<br>SEQUENCES | SLICE<br>THICKNESS | SPACING | FREQUENCY<br>FOV | PHASE<br>FOV | MATRIX  | TR         | TE   | NEX | TOTAL<br>SEQUENCE<br>TIME |
|-------------------------|--------------------|---------|------------------|--------------|---------|------------|------|-----|---------------------------|
| TRUE FISP SAGITAL       | 6.0                | 0.0     | 400              | 100          | 256x256 | 576.0<br>4 | 2.08 | 1   | 17 SEC                    |
| TRUE FISP FS<br>SAGITAL | 6.0                | 0.0     | 400              | 100          | 256x256 | 576.0<br>4 | 2.08 | 1   | 17 SEC                    |
| TRUE FISP CORONAL       | 6.0                | 0.0     | 400              | 100          | 256x256 | 576.0<br>4 | 2.08 | 1   | 17 SEC                    |
| TRUE FISP FS<br>CORONAL | 6.0                | 0.0     | 400              | 85.2         | 256x256 | 585.6<br>0 | 2.08 | 1   | 18 SEC                    |
| TRUE FISP AXIAL         | 9.0                | 0.9     | 380              | 80.5         | 256x256 | 531.2<br>6 | 2.1  | 1   | 22 SEC                    |
| TRUE FISP FS AXIAL      | 9.0                | 0.9     | 380              | 80.5         | 256x256 | 531.2<br>6 | 2.1  | 1   | 23 SEC                    |
| DWI                     | 6.0                | 1.2     | 400              | 98.5         | 256x256 | 6000       | 80   |     | 4.23 MIN                  |

Sequences parameters used for an MRE scan in the Siemens Aera scanner (1.5T). FOV – Field of view; TR – Repetition Time, TE – Echo Time; NEX - Number of excitations; SEC – seconds; MIN – minutes.

For a MRE scan, is mandatory that the patient arrives one hour prior to their appointment time to proceed for the bowel preparation through the ingestion of an oral contrast. All patients fasted for four to six hours before the scan. A safety questionnaire is filled to confirm that the individual is safe to go into the scanner. This questionnaire is always check and signed by the Radiographer before given the oral contrast solution. Patients under 16 years, the parents or guardian sign the questionnaire for them and, if a relative wants to escort the patient inside the scanner, they need to fill a dedicated safety questionnaire for themselves. The oral solution is given once the Radiographer has gone through all the safety checks. For patients under 16 years, a Klean.prep solution is given. This component is a powder to prepare an iso-osmotic bowel cleansing solution. The content is dissolved into a liter of water (forty-five milliliters for a liter of water) that the patient needs to drink from thirty to forty-five minutes. Smaller children drink as much as they can manage or if they cannot tolerate the solution, they keep drinking a liter of water over thirty minutes. Patients with and over 16 years, consume two bottles (five hundred milliliters each) of 2.5% mannitol solution diluted with water. Mannitol is a biphasic contrast agent, as stated before, widely used for MRE exams. It is required to document on the system the type of solution given to the patient as also the amount that has been ingested for the Radiologist to be informed.

When finished with the ingestion of the oral contrast, is asked to the patient to go for a walk around 5 minutes, to help the contrast to descend fill the bowel properly and to go to the toilet to empty their bladder before going to the scanner. The patient also must get changed, taking off all clothes except underwear that can be kept on if there is no metal and change into gowns provide by the department. This is required to avoid any artifacts that can provide from the metal in their clothes in the region of interest, or other accidents/incidents.

For an abdominal scan, it is not important if the patient goes head or feet-first, but it needs to be properly selected on the scanner before starting. Always in a supine position. The body array coil (receiver-type with 16 channels (GE) or 18 channels (Siemens) depending on the scanner that the exam is performed) is placed on the top of the patient (anterior) over the abdomen and pelvis ensuring that the whole bowel including the rectum is covered. The coil is secured to the body with straps also to give some compression, to help to reduce the peristaltic and respiratory movements.

The images are reviewed by a Paediatric Radiologist to check if post-contrast sequences are required. If no one available to review the Radiographer decides to apply a cinematic sequence in a coronal plane. If contrast is required, a Radiologist needs to come to cannulate the patient as the Radiographer is not allowed to cannulate patients under 16 years without having training in paediatric basic life support (BLS) (if it is not already done in the Paediatric Day Centre). A spoiled gradient echo (SPGR) FS sequence in a coronal plane is run with delays times of 30, 60, and 90 seconds. As referred above, these timings can demonstrate early intense mucosal enhancement followed by progressive transmural enhancement.

True FISP (fast imaging with steady-state precession – Siemens) and FIESTA (fast imaging employing – GE Medical system) are SSFP sequence. SSFP is an unspoiled sequence that uses the transverse magnetization generated with a single radiofrequency pulse contributes to the formation of several echoes. True FISP and FIESTA are T2W GRE sequences whose image contrast is determined by the T2/T1 ratio. The advantages of SSFP sequences include the highest possible SNR per unit time, better contrast-to-noise ratio (CNR) compared with spoiled GRE sequences, and increased signals, along with the improved speed of acquisition. These sequences are especially useful in patients who have difficulty holding their breath. It has proved beneficial in the delineation of bowel wall disease and overall bowel anatomy and the evaluation of renal and pelvic disease (41,64). These sequences are exquisitely sensitive to mesenteric changes such as hypervascularity, fibrofatty proliferation, and fistulae (33).

DWI measures the random movement of the water molecules within the tissues. Areas of high cellularity demonstrate restricted diffusion and, therefore, hyperintense signal. The magnitude of water molecule displacement is described quantitatively by the diffusion constant, which generally varies with the direction of diffusion. The amount of diffusion weighting is handled by the b-value of the diffusion gradient. It is proportional to the square of the amplitude and duration of the gradient applied. Diffusion is qualitatively evaluated on trace images and quantitatively by the parameter called apparent diffusion coefficient (ADC). Tissues with restricted diffusion are bright on the trace image and with hypointense signal on the ADC map. This technique is typically acquired with an EPI sequence (41,42,65). DWI has been found useful in inflammatory bowel disease. According to Vinit Baliyan *et al* (2016), combined with MRE, has higher diagnostic accuracy (92%) than MRE alone (79%) for disease activity. It has also been valuable in the detection and characterization of extraintestinal manifestations and complications, and the mesenteric and SB tumour detection (65). The technique is feasible in infants and children, even during free breathing (66).

SPGR is a spoiled GRE sequence. It uses a gradient spoiler at the end of the repetition and additionally vary the phase of each RF pulse to eliminate transverse magnetization, providing pure T1 contrast. The goal is to avoid the signal variations due to off-resonance effects by essentially averaging the profile. RF-spoiled GRE imaging is commonly used clinically for contrast-enhanced imaging since the pure T1W highlights the shortened-T1 due to the presence of a contrast agent (16,35). T1W 3D GRE is performed during a BH. In small children, it can be performed with free breathing and a high number of excitations (9). These are widely used to assess the pattern of bowel enhancement (33).

Because water and fat have different resonance frequencies, it is possible to selectively saturate the spectral peak of either water or fat by applying a frequency-selective RF pulse before imaging. The resonant frequency of fat protons and water protons differs by 3.5 parts per million, which, at a field strength of 1.5 T, causes fat to precess 225 Hz slower than water. The *spoiling* technique, a short frequency-selective 90° RF pulse that is applied to rotate the fat magnetization into the transverse plane. While in the transverse plane, the fat magnetization is dephased by the application of a spoiler gradient, leaving only the longitudinal magnetization of water for excitation during the next cycle. This technique is applied in routine clinical MR imaging (41).

Cine imaging refers to the ability to acquire multiple images throughout a specific cycle (cardiac or respiratory). This is the standard method for global and regional functional cardiac imaging and analysis. Requires a data acquisition over a small number of consecutive heartbeats within a single BH. In gastrointestinal (GI) imaging, single-shot techniques are used to rapidly generate images that are then repeated, during a BH or

during free breathing to capture the irregular motion in the GI tract. The most widely used sequence performed is the SSFP sequences like the True FISP and FIESTA. This sequence is particularly attractive for GI motility due to its capability for rapid imaging with a high SNR and excellent image contrast, resulting in excellent quality dynamic images, acquired with a high temporal resolution.

## **2.8 MRI department in the University Hospitals of Leicester**

The University Hospitals of Leicester (UHL) is a network of hospitals that belongs to the National Health System (NHS). It is a teaching trust separated into three bases: Leicester Royal Infirmary (LRI), Glenfield Hospital (GH), and Leicester General Hospital (LGH). The Trust serves a population of more than 1,000,000 people in the areas of Leicester, Leicestershire and Rutland and employs more than 10,000 staff.

The LRI is the main hospital, located in the center of Leicester city. It always had an Emergency Department (ED). In April 2018, with the new ED floor constructed, a dedicated paediatric ED was created. The hospital has a capacity of 900 beds. The LRI as their paediatric hospital integrated. Most of the paediatric exams are done in the LRI, only cardiac exams are done in GH that is a specialised hospital. The Radiology department is divided into three departments: cross-sectional imaging (CT and MRI), x-ray and interventional. The cross-sectional team includes 24 staff members. There is no Paediatric Specialist Radiographer. The paediatric MRI service started in approximately April 1993. In the Trust, there are 6 Paediatric Consultants Radiologist. There is none dedicated MRI scanner. In the hospital, the paediatric scans can be done under or not GA. For the outpatients not going under GA procedure, there are approximately 12 patients per weeks, Monday to Sunday. For the GA procedures, the department has GA lists that are 4 sessions (Tuesday and Thursday in the morning and afternoon) with 3 patients in each session with a total of 12 patients per week. The GA team that monitors the scans is paediatric specialized. The most frequent MRI scans done in children are with a neurologic indication such as heads and spines followed by abdominal imaging and musculoskeletal.

## **2.9 Objectives**

This study aims to explore the factors that influence the image quality in MRI abdominal paediatric studies and compare them with and without conscious sedation appliance.

Additionally, we intend with this study:

- Explore the non-invasive factors that improve the image quality between age groups improving the protocols;
- Produce a checklist of good practices and strategies to apply to the child and its parents, in a way to reduce the use of GA. Each checklist was adjusted to the vulnerable groups either by the age or pathologic condition;
- Empower the Radiographer professional skills in MRI studies performance and generate a group of good practices in the patient preparation for the child in this hospital group.

It is, therefore, important to compare the MRE images with and without sedation or anaesthetic and explore the risk-benefit in the use of techniques to decrease, whenever, if possible, the consciousness decay in this population, replacing these procedures by techniques less invasive.

## **3 Materials and methods**

### **3.1 Study design**

MRI scans considered to this study were acquired between 2014 and 2018 making this a retrospective, observational, and exploratory-quantitative study. The retrospective study, also, has a limitation that does not allow handling the data or variables of the protocol acquisition. In this case, is a potential structuring element because the researcher can assess effectively the protocols applied without influence them.

### **3.2 Materials**

The exams were performed in two 1,5 Tesla MRI scanners (Magnetom Aera, Siemens Healthineers, Erlangen, Germany; and Optima™ MR450w GEM, GE Healthcare, Chicago Illinois, USA) and one 3 Tesla MRI scanner (Discovery™ MR750w GEM, GE Healthcare, Chicago Illinois, USA).

The sequences were observed via the Picture Archiving and Communication System (PACS). Each assessor received a list with a random distribution of the exams performed with or without general anaesthetic (GA). The images could be found by using the patient hospital number and the date that the exam was completed as the same patient had several scans during the years (attachment VI). The assessors reviewed all the sequences completed in each exam through an independent observation, not having the age and GA conditions in account, only the image quality and patient preparation. No time was limited to the assessor to review and classify the images.

### **3.3 Population and sample**

The population of this study were all children that performed abdominal MRI studies in the University Leicester Hospitals (UHL), between February 2014 and December 2018. Was chosen this temporal range to decrease the “memory” bias in the experts, because some of them still have seen the images when the study was performed. The selection of the sample was based on the age group and the type of scan. Therefore, the inclusion criterion was children between the age of 4 and 16 years that had abdominal scans performed under or not GA. In total 73 exams were evaluated.

### **3.4 Sample characterization**

The pediatric age range considered was: [4-8 years [, [8-12 years [, [12-15 years [, and [15-18 years]. The range of ages of the 73 patients was with the youngest with 4 years

old and the oldest with 16 years old, [min 4; Max 16] with an average of 11,97 years old. Regarding the patient's gender, 39 were male (54,32%) and 34 were female (46,58%).

### 3.5 Variables

The variables considered in this study where:

- Independent variable – MRI performed with, or not, GA; (Age – moderator variable);
- Dependent variable – Global image quality (operationalized by contrast resolution, spatial resolution, SNR and artifacts).

### 3.6 Data collection

To evaluate the quality of the scans performed a questionnaire was done. This survey consists in a *Likert* scale check list with three evaluation score: suboptimal - if the image quality or patient preparation were not enough to identify the pathology or evaluate the abdominal structures; optimal – if even with some artifacts the image quality or poor patient preparation, was able to be diagnostic; excellent for diagnostic – such the patient preparation and the image quality were standard. A group of two Senior Radiographers and two Radiologists with more than 5 years' experience, that agreed to participate in this study, had to visually evaluate the image quality in each scan taking in account its value to diagnosis, contrast resolution, spatial resolution, SNR and artifacts that can be observed in the 73 scans performed.

The exams were observed in reporting stations and the raters had to log in to PACS to analyse and evaluate images' quality.

The timeline of this exam's performance was within four years and in different conditions, so the sequences evaluated were different depending on the scanner used and, on the protocol followed.

The raters could also comment on the exam given their opinion about the patient preparation, if any artifacts seen and which could be identified, or what could be improved. Their comments were divided into five categories being 1) equipment/operator (coverage, bad positioning, signal loss, hardware, or software artifacts), 2) protocol (if correct sequences applied), 3) patient collaboration (if bowel was or not properly field, patient movement, breathing artifacts), 4) pathology or 5) no comment given.

### 3.7 Ethical approaches

A formal letter was written to the MRI Superintendent asking for permission to access the patients' scan and files, agreeing that patients' confidentiality was kept (attachment I). Also, a project planner was filled to have permission from the Clinical Audit Team to proceed with this study (attachment II).. No patient hospital number or personal details had been kept after the data collection.

Manager of the data, nominated to this task was removed the patient's identification, and each study was identified by a serial number. This was approved by the competent entities of the hospital and the data collected by the technical superintendent of the department after its anonymization and gave a series number to its identification.

As routinely for all MRI scans, the guardians had to fill a safety questionnaire for the patient due to safety concerns (attachment IV). The consent to perform the MRI under or not GA, was also performed before the images acquisition (attachment V).

### 3.8 Methods of data processing and treatment

A group of two Senior Radiographers and two Paediatric Consultants Radiologists with 5 or more years of professional experience, (expert's panel) analyse abdominal MRI scans of paediatric patients between 4 to 16 years old. The observers evaluated the images by a *Likert scale* created to this proposal, having in mind the image quality, in exams that were performed under or not GA.

A document was given with the 73 exams, where each assessor received a list with a random distribution of the exams performed with or without GA. The exams were enumerated so they need to follow a specific order, but they could access the images through the patient hospital number. This assessment was done in the hospital computers, more specific, in the Radiologists reporting stations. The assessment of the sequences was done independently as the time for each one of them.

Due to the discrepancy of the exam's timeline, there were differences from the sequences used as the more recent exams, the protocol has been updated.

To analyse the data collected, it was used the statistic test of *Fleiss' Kappa* to evaluate the agreement between the expert's opinions regarding the image's quality.

This test measures the agreement between two or more raters, where agreement due to chance is factored out. If a fixed number of people assign numerical ratings to several items, then the *kappa* will give a measure for how consistent the ratings are.

The *kappa* can be defined as:

$$k = \frac{(\bar{P} - \bar{P}_e)}{(1 - \bar{P}_e)}$$

$(P - P_e)$ : degree of agreement that achieves above chance;

$(1 - P_e)$ : degree of agreement that is attainable above chance.

If the raters are in complete agreement, then  $k = 1$ ; if there is no agreement among the raters then  $k < 0$ .

On the following table (Table 1) it is possible to find the meaning of each kappa ( $k$ ) value meeting with Shweta *et al* (2015):

Table 3.1 - Interpretation of  $k$  values (67).

| $k$         | Interpretation        |
|-------------|-----------------------|
| $< 0$       | Poor agreement        |
| 0,01 – 0,20 | Slight Agreement      |
| 0,21 – 0,40 | Fair Agreement        |
| 0,41 – 0,60 | Moderate Agreement    |
| 0,61 – 0,80 | Substantial Agreement |
| 0,81 – 1,00 | Almost perfect        |

When performing a hypothesis test, a  $p$ -value helps to determine the significance of the results obtained.

The  $p$ -value weights the strength of evidence, and it is a number between 0 and 1 being, was considered as  $\alpha = 5\%$  and interpreted in the following way:

- A small  $p$ -value (typically  $\leq 0.05$ ) indicates strong evidence against the null hypothesis, so the null hypothesis is rejected.
- A large  $p$ -value ( $> 0.05$ ) indicates weak evidence against the null hypothesis, this way we accept the null hypothesis.

When  $p$ -value very close to the cut off (0.05) is marginal what means it can go either way (67,68).

The statistic test used in this study, as the variables record, were performed through the Microsoft Excel program.

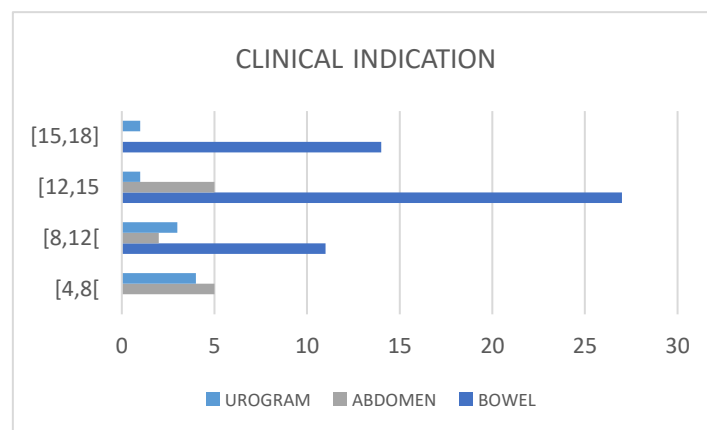
## 4 Results

Of the 73 exams, 52 were MR Enterogram (MRE), 12 abdominal scans and 9 urograms. 40 of the exams the pathology was known (54,79%) and 33 of the exams was their primary diagnostic (45,21%). 63 of the scans (86,30%) were not performed under general anaesthetic (GA). The scans under GA – 8 - were done within the age group [4,8[, 1 in the age group [8,12[ and 1 in the age group [12,15[ (table 4.1). The one performed on the age group [12,15[ presented learning disabilities.

Table 4.1 - Exams that required or not General Anaesthetic (GA) per group age.

|         | WITHOUT GENERAL ANAESTHETIC | WITH GENERAL ANAESTHETIC |
|---------|-----------------------------|--------------------------|
| [4,8[   | 5                           | 8                        |
| [8,12[  | 11                          | 1                        |
| [12,15[ | 32                          | 1                        |
| [15,18[ | 15                          | N/A                      |

The main clinical requirements for the age group [4,8[ was abdominal pathology followed by urograms; from [8,12[ the main indication was MRE followed by urograms and abdominal pathology; from [12,15[ the main indication was MRE followed by abdominal pathology and urograms; from [15,18[ the main indication was MRE followed by urograms (Graph 4.2).

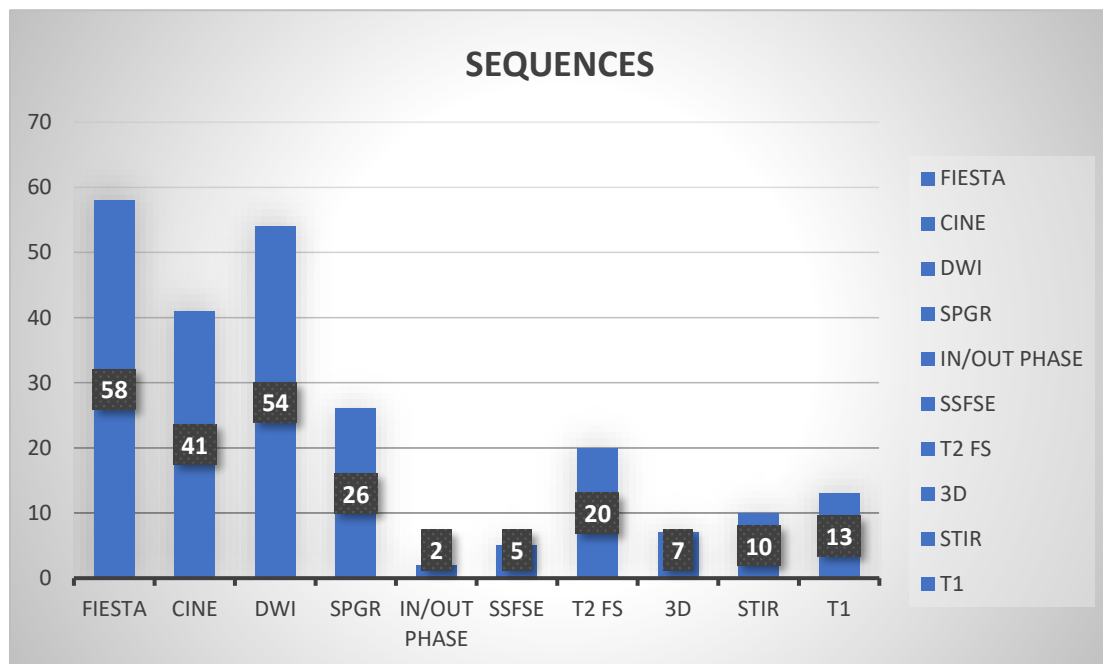


Graph 4.2 – Graphic illustrations of the clinical requirements in the age groups.

As described before, there is a dedicated anaesthetic room for the GA sessions in the department. The scans under GA were then performed between the GE scanner – 3 in the 3T scanner and 7 over the 1.5T scanner. Only one of the exams performed in the 1.5T GE scanner was a MRE, being the rest abdominal or urograms scans.

The scans performed without GA, 25 of them were performed in the 3T GE scanner, 7 in the 1.5T GE scanner and 31 in the 1.5T Siemens scanner. Of the 53 MRE, 21 were performed in the 3T GE scanner, 5 in the 1.5T GE scanner and 25 in the 1.5T Siemens scanner.

Over 240 sequences were analysed. The graph 4.3 demonstrate the number of each sequence and it is possible to see that the main used were FIESTA (axial, coronal, and sagittal planes), DWI (coronal planes) and cinematic (coronal planes) sequences. As described previously, SSFP sequences, like FIESTA and TRUEFISP, are mainly applied for abdominal scans due to the use of breath-holds or respiratory-triggering techniques that helps to reduce motion artifacts. Also, DWI sequences are less sensitive to artifacts as they are usually acquired with an echo-planar imaging (EPI), being widely used for abdominal imaging.



Graph 4.3 – Graphic illustration of the percentage of the sequences used in the exams studied.

The tables below, table 4.4 and 4.5, it is possible to observe the results obtained for the survey (attachment VI) answered by the two Radiographers and Paediatric Consultant Radiologists (table 4.4) and the outputs after the application of Fleiss' Kappa test (Table 4.5).

Table 4.4 - Classification given by the four raters to each exam per age.

| AGE GROUP | CLASSIFICATION |         |                          |
|-----------|----------------|---------|--------------------------|
|           | SUB-OPTIMAL    | OPTIMAL | EXCELLENT FOR DIAGNOSTIC |
| [4,8[     | 17             | 17      | 2                        |
| [8,12[    | 19             | 30      | 15                       |
| [12,15[   | 39             | 65      | 32                       |
| [15,18]   | 15             | 35      | 6                        |

Table 4.5 – Outputs from Fleiss' Kappa analysis tool.

|         | TOTAL        | EXCELLENT FOR<br>DIAGNOSTIC | OPTIMAL     | SUB-OPTIMAL |
|---------|--------------|-----------------------------|-------------|-------------|
| KAPPA   | -0,003927473 | 0,08498                     | -0,08224255 | 0,01038181  |
| S.E.    | 0,034489256  | 0,04778                     | 0,047781848 | 0,04778185  |
| Z-STAT  | -0,113875273 | 1,77844                     | -1,7212091  | 0,21727519  |
| P-VALUE | 0,909336667  | 0,07533                     | 0,085212887 | 0,82799389  |
| LOWER   | -0,071525174 | -0,0087                     | -0,17589325 | -0,0832689  |
| UPPER   | 0,063670227  | 0,17863                     | 0,01140815  | 0,10403251  |

Table 4.6 demonstrates the kappa and p-values after the application of the Fleiss' Kappa test, demonstrating the level of agreement between the assessors for the three classifications: excellent for diagnostic, optimal, sub-optimal. The classification was given having in mind the patient preparation and image quality for diagnostic. The classification 'Excellent for Diagnostic', *kappa* is equal to 0,08 (slight agreement); for the classification 'Optimal' *kappa* is -0,08 (poor agreement); the classification 'Sub-optimal', *kappa* is 0,01 (poor agreement). For the three classifications,  $p > 0,05$ , that indicates weak evidence against the hypothesis.

Table 4.6 - Kappa and p-values for the classification presented after applying the Fleiss' Kappa test.

| CLASSIFICATION           | KAPPA  | INTERPRETATION   | P-VALUE |
|--------------------------|--------|------------------|---------|
| EXCELLENT FOR DIAGNOSTIC | 0.085  | SLIGHT AGREEMENT | 0.075   |
| OPTIMAL                  | -0.082 | POOR AGREEMENT   | 0.085   |
| SUB-OPTIMAL              | 0.010  | POOR AGREEMENT   | 0.828   |

Table 4.7 indicates the comments given by the raters for each exam. For the group age 4,8[, the major comment presented was due to artifacts, mostly breathing. For the older age groups [8,12[, 12,15[ and [15,18[, the main comment given was regarding the patient collaboration that encompassed the patient preparation and motion artifacts.

Table 4.7 – Answers of the raters regarding the exam’s comments, separate by categories and per age groups.

| AGE GROUP | COMMENTS CATEGORIES |          |                      |           |           |            |
|-----------|---------------------|----------|----------------------|-----------|-----------|------------|
|           | EQUIPMENT           | PROTOCOL | PATIENT COLABORATION | ARTIFACTS | PATHOLOGY | NO COMMENT |
| [4,8[     | 5                   | 4        | 2                    | 21        | 0         | 6          |
| [8,12[    | 7                   | 0        | 33                   | 7         | 1         | 14         |
| [12,15[   | 12                  | 3        | 73                   | 6         | 0         | 42         |
| [15,18]   | 6                   | 3        | 33                   | 0         | 0         | 14         |

## 5 Analysis and discussion of results

The main goal of this study is to evaluate the image quality in MR Enterogram (MRE) and abdominal studies performed in the UHL from February 2014 to December 2018, in children between the ages of 4 to 16 years old that gone under or not general anaesthetic (GA). This has the purpose to demonstrate if the preparation of the patient is properly done and if the operator can recognize it as well to understand if the quality of the sequence is appropriate for a diagnostic scan. The Radiographer as the Radiologist reviews different sequences in different planes (axial, coronal, and sagittal) depending on what was protocolled at the time of the scan.

When a child requires to be submitted to medical exam under a GA there are two major reasons: the child is too young to understand what is happening and capable to follow instructions or they have learning disabilities that do not allow them to maintain the concentration for the scan. Children are also unable to hold their breath adequately until they are about 8 years of age (8,69).

By analysing table 4.1, it is possible to observe that most cases that occurred under GA were in the age group [4,8]. Only two other cases were observed in the age groups [8,12] and [12,15] knowing that the one in the older group had learning disabilities.

Sergio Salerno *et al* (2018) states that long scan times like in MRI, make sedation or GA indispensable in paediatry. The principal short-term risks are under-sedation or over-sedation. Under-sedation can be an inadequate reduction of movements to obtain diagnostic images. In younger children, over-sedation increases the risk of desaturation or apnoea. Practices for the induction of GA, as masks or cannulas, can also create anxiety in the child (70).

According to Melissa M. Masaracchia *et al* (2017), children with developmental disabilities are three times more likely to experience hypoxia with deep sedation for diagnostic imaging when compared to children without disability. The incidence of adverse events was quoted to be between 0% and 10.4% for this subset of patients, with the highest rate noted to be in inpatients who performed GA for imaging (10).

As observed in graph 4.2, the main exam analysed in this sample were MRE in the age groups [8,12] and [12,15]. In age group [4,8] the main clinical indication is abdominal pathology and urograms. For example, Wilms' tumour is the most common malignant tumour arising from the kidney in children. According to *Michael Riccabona* (2008), although MRI was initially used in children mainly for neuroradiological purposes, it has

in the past years increasingly and successfully been applied to several paediatric abdominal conditions (28).

Analysing the *kappa* value in table 4.6 that provides the degree of agreement between raters, for the classification 'Excellent for Diagnostic', *kappa* is equal to 0,08 (slight agreement); for the classification 'Optimal' *kappa* is -0,08 (poor agreement); the classification 'Sub-optimal', *kappa* is 0,01 (poor agreement). Therefore, this suggests that the exams that were classified as being 'Excellent for Diagnostic', most or all the raters agreed with the image quality. Opposite, the 'Optimal' or 'Sub-optimal' classifications, the agreement between raters was not the same. It is possible to conclude that the rater's categorization differs. For example, for the same exam, both Radiologist would classify the scan as 'Optimal', but the Radiographers would say that the scan was 'Sub-optimal' exam. Although when the Radiographer believe that the image does not comply within the required standards, for the Radiologist is sufficient to give a diagnosis form it. It is noted that the images may have some artifacts in the Radiographer's opinion that what always perform perfect images, however they allowed a diagnostic answer to the clinical history. This fact can explain the disagreement between the two professional categories in the same studies.

When considering *p*-value (table 4.6), all the three classifications have  $p > 0,05$ , that indicates weak evidence against the hypothesis. It means that there is no agreement between raters. To rephrase, these values are individual (for each exam) and it does not mean that raters have negatively evaluated questions.

There are other details to have into consideration in this analysis. By studying table 4.7 that gives the comments given by each one of the raters, is possible to see that the main category criticizes is the patient collaboration, mainly in the age group [12,15].

There was a difference when the exams were assessed by the Radiographer and the Radiologist. The Radiographers were able to identify the breathing and movement artifacts. However, they did not comment regarding the bowel filling and distension that is one of the main comments given by the Radiologist. From the comments presented, in 52 MRE exams, only 6 of them (approximate 11,6%) had a proper bowel filling that reach the terminal ileco-junction.

In Brett Mollard *et al* (2016) article, he determines that the oral contrast opacified the distal and terminal ileum is properly filled in approximately 39% of the examinations and that the contrast failed to reach the ileum in 21% of examinations in his study. Also, based in his experience performing MRE in young children for more than 5 years, the

lack of opacification of the distal small bowel uncommonly results in a diagnostic dilemma regarding the presence or absence of inflammation (22).

For the age group [4,8], the group in which the scans were mainly performed under GA, the major comment was regarding artifacts. Mostly breathing artifacts. This occurs due to the non-capacity of having a regular respiratory cycle when the child is intubated.

It is often forgotten the need to control the ventilation and breath-holding (BH) to reduce the motion artifact in younger children. BH for MRI can cause hypoxemia and considerably impact in the hemodynamic stability. All of which requires intervention and scan interruption. (8,11). Controlled apnea during GA can be used to eliminate respiratory motion. Nevertheless, this intends to increase the examination time and faster sequences also have their limitations. They have reduced SNR and resolution in comparison with longer sequences (9).

## 6 Conclusions

The demand for Magnetic Resonance Imaging (MRI) in the paediatric population is increasing every day due to the benefit of non-ionizing radiation to children. Still, this exam requires that the child keeps immobilized and calm throughout the procedure. In most cases, this condition is impractical, with high frequency in the lower old ranges.

Therefore, the use of sedation or general anaesthesia (GA) is required to achieve a quality diagnostic image. However, this procedure has risks such as high cost, the requirement of an anaesthetic team to be present during the exam, and availability of patient recovery room. While an MRI scan under GA can take up to 55 minutes to 2 hours or more depending on the patient condition, when performing without the GA, can take 30 minutes to a maximum of 45 minutes. Furthermore, complications like hypoxia and idiopathic hyper activeness can be generated. This examination is predominantly needed in children with abdominal diseases or neurologic disabilities. During MRI abdominal examinations (e.g. MR Enterogram (MRE)), extra attention to details is required to achieve good image quality such as patient preparation, ingestion of the oral contrast, adjustment of fast protocols as also the instructions for breath-holds or the need to use triggering techniques in a way to obtain images free from motion artifacts and that can best show the pathology or region of interest with high accuracy and diagnostic quality.

Good handling and management of these cases are crucial, and these will be possible only with a team effectively trained.

It is, subsequently, important to compare the MRE images with and without sedation or GA and explore the risk-benefit in the use of techniques to decrease, whenever possible, the consciousness decay in this population replacing these procedures by techniques less invasive.

It is fundamental in paediatric MRI scans that the Radiographer feels confident enough and his aware of the challenges that can occur with these patients. Would be useful if a play specialist would be involved to help with younger children.

With MRE exams, would be beneficial for the department as well for the expansion of professional skills that talks and continuing professional development (CPD) sessions would be organised with paediatric Radiologists to improve the Radiographer's interpretation of a diagnostic exam and develop critical analysis, for example, to understand if a patient needs more time for the bowel to be properly filled and how to improve the scan quality.

This research presents various limitations. First, for being a retrospective study. The number of Radiographers and Radiologists with more than 5 years' experience available to participate in this project was one of the main obstacles. Also, the period scale that these exams were performed generates another concern. To obtain an acceptable number of abdominal MRI under GA, the search of the exams required that the timeline would be wider as in the Leicester Royal Infirmary, the number of abdominal scans under GA is reduce. There was also a delay in processing data since it took several weeks for the Radiographers and the Radiologist to answer the survey and afterwards the post-processing of data collection (application of statistic tests and its analysis). Besides these difficulties, the acceptance of the study in the hospital was also a challenge that delayed the development of the study.

As technical limitations we can evidence the different equipment's used in the images acquisition and include studies more than MRE like urograms and abdominal exams to enlarge the sample.

Would be useful to know other variables such as the Radiographer experience that performed the scan and study the impact in the image due to the different scanners and protocols used. Also, the tissue composition in the child and, the experience and training in immobilization and distraction techniques would be other factors valuable to assess.

In this study, even though that the number of MRI that was performed under a GA procedure was low, it is imperative to develop an educational training to empower the Radiographers and assistants in immobilization, relaxation, and distraction techniques in a way to minimise the number of anaesthesia's given. Another focus of the Radiology team should be the adaptation of the scanners room, the scanner itself, devices, and accessories.

Instructional videos such as <https://www.gosh.nhs.uk/medical-information/procedures-and-treatments/mri-scan-without-sedation-or-general-anaesthetic/your-child-having-mri-scan-video-podcast> and other informative instruments should be given prior to the parents to obtain a better collaboration and preparation of the child for the exam as an example that we produce that can been see on Attachment VII.

This study contributed to highlight this problem to the teams in the varied imaging departments, to talk, think and work around them, raising professional's awareness in applying the best practices. Likewise, a benefit from this study was to increase the practices on assessment, imaging audit, critical analysis, and exchange experiences.

In this field, the evidence based on the best practices and good experiences have a strong value. We think that a long-time study will contribute to reduce the number of MRI exams under GA or sedation; and consequently, develop the department workflow as well as the reduction of pediatric waiting lists for MRI scans.

## 7 References

1. Jaimes C, Gee MS. Strategies to minimize sedation in pediatric body magnetic resonance imaging. *Pediatr Radiol*. 2016;46(6):916–27.
2. Reilly L, Byrne AH, Ely E. Does the use of an immobilizer provide a quality MR image of the brain in infants? *J Radiol Nurs [Internet]*. 2012;31(3):91–6. Available from: <http://dx.doi.org/10.1016/j.jradnu.2012.04.002>
3. Shearrer GE, House BT, Gallas MC, Luci JJ, Davis JN. Fat imaging via magnetic resonance imaging (MRI) in young children (ages 1-4 years) without sedation. *PLoS One*. 2016;11(2):1–10.
4. Li J, Li Q, Dai X, Li J, Zhang X. Does pre-scanning training improve the image quality of children receiving magnetic resonance imaging?: A meta-analysis of current studies. *Medicine (Baltimore)*. 2019;98(5):e14323.
5. Barnea-Goraly N, Weinzimer SA, Ruedy KJ, Mauras N, Beck RW, Marzelli MJ, et al. High success rates of sedation-free brain MRI scanning in young children using simple subject preparation protocols with and without a commercial mock scanner-the Diabetes Research in Children Network (DirecNet) experience. *Pediatr Radiol*. 2014;44(2):181–6.
6. Panus J, Goldschmidt K. Creative use of technology for distracting children for MRIs. *J Pediatr Nurs [Internet]*. 2014;29(1):94–5. Available from: <http://dx.doi.org/10.1016/j.pedn.2013.10.006>
7. Netzke-Doyle V. Distraction strategies used in obtaining an MRI in pediatrics: A review of the evidence. *J Radiol Nurs [Internet]*. 2010;29(3):87–90. Available from: <http://dx.doi.org/10.1016/j.jradnu.2009.12.005>
8. Dagia C, Ditchfield M. 3 T MRI in paediatrics: Challenges and clinical applications. *Eur J Radiol*. 2008;68(2):309–19.
9. Chavhan GB, Babyn PS, Vasanaawala SS. Abdominal MR imaging in children: Motion compensation, sequence optimization, and protocol organization. *Radiographics*. 2013;33(3):703–19.
10. Masaracchia MM, Tsapakos MJ, McNulty NJ, Beach ML. Changing the paradigm for diagnostic MRI in pediatrics: Don't hold your breath. *Paediatr Anaesth*. 2017;27(9):880–4.
11. Munn Z, Jordan Z. Interventions to reduce anxiety, distress, and the need for sedation in pediatric patients undergoing magnetic resonance imaging: A systematic review. *J Radiol Nurs [Internet]*. 2013;32(2):87–96. Available from: <http://dx.doi.org/10.1016/j.jradnu.2012.08.003>
12. Smith EA, Dillman JR. Current role of body MRI in pediatric oncology. *Pediatr Radiol [Internet]*. 2016;46(6):873–80. Available from: <http://dx.doi.org/10.1007/s00247-016-3560-8>
13. C. L, K.P. K, D. L, R. F, C. T, S.L. S, et al. Organ doses for reference pediatric and adolescent patients undergoing computed tomography estimated by Monte

- Carlo simulation. *Med Phys* [Internet]. 2011;38(3):1196–205. Available from: <http://www.embase.com/search/results?subaction=viewrecord&from=export&id=L361353295%0Ahttp://dx.doi.org/10.1118/1.3544658>
14. Brenner DJ, Elliston CD, Hall EJ, Berdon WE. Estimated risks of radiation-induced fatal cancer from pediatric CT. *Am J Roentgenol*. 2001;176(2):289–96.
  15. Zens TJ, Rogers AP, Riedesel EL, Leys CM, Ostlie DJ, Woods MA, et al. The cost effectiveness and utility of a “quick MRI” for the evaluation of intra-abdominal abscess after acute appendicitis in the pediatric patient population. *J Pediatr Surg* [Internet]. 2018;53(6):1168–74. Available from: <https://doi.org/10.1016/j.jpedsurg.2018.02.078>
  16. McCarville MB. What MRI can tell us about neurogenic tumors and rhabdomyosarcoma. *Pediatr Radiol* [Internet]. 2016;46(6):881–90. Available from: <http://dx.doi.org/10.1007/s00247-016-3572-4>
  17. Edwards AD, Arthurs OJ. Paediatric MRI under sedation: Is it necessary? What is the evidence for the alternatives? *Pediatr Radiol*. 2011;41(11):1353–64.
  18. Shin HJ, Kim MJ, Lee MJ, Kim HG. Comparison of image quality between conventional VIBE and radial VIBE in free-breathing paediatric abdominal MRI. *Clin Radiol* [Internet]. 2016;71(10):1044–9. Available from: <http://dx.doi.org/10.1016/j.crad.2016.03.018>
  19. Ruangwattanapaisarn N, Radiology T, Hospital R, Loening AM, Saranathan M, Vasanaawala SS, et al. Faster pediatric 3-T abdominal magnetic resonance imaging: comparison between conventional and variable refocusing flip-angle single-shot fast spin-echo sequences. *Pediatr Radiol*. 2016;45(6):847–54.
  20. Ahmad R, Hu HH, Krishnamurthy R, Krishnamurthy R. Reducing sedation for pediatric body MRI using accelerated and abbreviated imaging protocols. *Pediatr Radiol*. 2018;48(1):37–49.
  21. Smolinski S, George M, Dredar A, Hayes C, Rakita D. Magnetic resonance enterography in evaluation and management of children with crohn’s disease. *Semin Ultrasound, CT MRI* [Internet]. 2014;35(4):331–48. Available from: <http://dx.doi.org/10.1053/j.sult.2014.05.008>
  22. Mollard BJ, Smith EA, Lai ME, Phan T, Christensen RE, Dillman JR. MR enterography under the age of 10 years: a single institutional experience. *Pediatr Radiol*. 2016;46(1):43–9.
  23. Ziech MLW, Hummel TZ, Smets AMJB, Nievelstein RAJ, Lavini C, Caan MWA, et al. Accuracy of abdominal ultrasound and MRI for detection of Crohn disease and ulcerative colitis in children. *Pediatr Radiol*. 2014;44(11):1370–8.
  24. Naganuma M, Hosoe N, Kanai T, Ogata H. Recent trends in diagnostic techniques for inflammatory bowel disease. *Korean J Intern Med*. 2015;30(3):271–8.
  25. Athanasakos A, Mazioti A, Economopoulos N, Kontopoulou C, Stathis G, Filippiadis D, et al. Inflammatory bowel disease—the role of cross-sectional

- imaging techniques in the investigation of the small bowel. *Insights Imaging*. 2015;6(1):73–83.
26. Taylor SA, Mallett S, Bhatnagar G, Baldwin-Cleland R, Bloom S, Gupta A, et al. Diagnostic accuracy of magnetic resonance enterography and small bowel ultrasound for the extent and activity of newly diagnosed and relapsed Crohn's disease (METRIC): a multicentre trial. *Lancet Gastroenterol Hepatol*. 2018;3(8):548–58.
  27. Gauci J, Sammut L, Sciberras M, Piscopo N, Micallef K, Cortis K, et al. Small bowel imaging in crohn's disease patients. *Ann Gastroenterol*. 2018;31(4):395–405.
  28. Michael R. Potential of MR-imaging in the paediatric abdomen. *Eur J Radiol*. 2008;68(2):235–44.
  29. Rehani MM, Yang K, Melick ER, Heil J, Šalát D, Sensakovic WF, et al. Patients undergoing recurrent CT scans: assessing the magnitude. *Eur Radiol*. 2020;30(4):1828–36.
  30. Zacharias C, Alessio AM, Otto RK, Iyer RS, Philips GS, Swanson JO, et al. Pediatric CT: Strategies to lower radiation dose. *Am J Roentgenol*. 2013;200(5):950–6.
  31. Karami V, Zabihzadeh M, Shams N, Gholami M. Radioprotection to the gonads in pediatric pelvic radiography: Effectiveness of developed bismuth shield. *Int J Pediatr*. 2017;5(6):5153–66.
  32. Darge K, Anupindi SA, Jaramillo D. MR Imaging of the Abdomen and Pelvis in Infants, Children, and Adolescents. *Radiology [Internet]*. 2011 Oct;261(1):12–29. Available from: <http://pubs.rsna.org/doi/10.1148/radiol.11101922>
  33. Gee MS, Harisinghani MG. MRI in patients with inflammatory bowel disease. *J Magn Reson Imaging*. 2011;33(3):527–34.
  34. Zaitsev M, Maclaren J, Herbst M. Motion artifacts in MRI: A complex problem with many partial solutions. *J Magn Reson Imaging*. 2015;42(4):887–901.
  35. Lee JH, Choi YH, Cheon JE, Lee SM, Cho HH, Shin SM, et al. Improved abdominal MRI in non-breath-holding children using a radial k-space sampling technique. *Pediatr Radiol*. 2015;45(6):840–6.
  36. Jaimes C, Kirsch JE, Gee MS. Fast, free-breathing and motion-minimized techniques for pediatric body magnetic resonance imaging. *Pediatr Radiol*. 2018;48(9):1197–208.
  37. Chandarana H, Block KT, Winfeld MJ, Lala S V., Mazori D, Giuffrida E, et al. Free-breathing contrast-enhanced T1-weighted gradient-echo imaging with radial k-space sampling for paediatric abdominopelvic MRI. *Eur Radiol*. 2014;24(2):320–6.
  38. Krupa K, Bekiesińska-Figatowska M. Artifacts in magnetic resonance imaging. *Polish J Radiol*. 2015;80(1):93–106.

39. Budrys T, Veikutis V, Lukosevicius S, Gleizniene R, Monastyreckiene E, Kulakiene I. Artifacts in magnetic resonance imaging: how it can really affect diagnostic image quality and confuse clinical diagnosis? *J Vibroengineering* [Internet]. 2018 Mar 31;20(2):1202–13. Available from: <http://www.jvejournal.com/Vibro/article/JVE-19756.html>
40. Alfudhili K, Masci PG, Delacoste J, Ledoux JB, Berchier G, Dunet V, et al. Current artefacts in cardiac and chest magnetic resonance imaging: Tips and tricks. *Br J Radiol*. 2016;89(1062).
41. Weishaupt D, Köchli VD, Marincek B. How does MRI work? How does MRI work? 2003.
42. Courtier J, Rao AG, Anupindi SA. Advanced imaging techniques in pediatric body MRI. *Pediatr Radiol*. 2017;47(5):522–33.
43. Runge SB, Christensen NL, Jensen K, Jensen IE. Children centered care: Minimizing the need for anesthesia with a multi-faceted concept for MRI in children aged 4–6. *Eur J Radiol* [Internet]. 2018;107(July):183–7. Available from: <https://doi.org/10.1016/j.ejrad.2018.08.026>
44. Mathur A, Kamat A, Philp B, Tabb J, Thomas R, Mahajan P, et al. Effect of Music Interventions on Sedation in Children Undergoing Magnetic Resonance Imaging: Clinical Trial. *Int J Child Heal Nutr*. 2016;5(2):63–74.
45. Mastro KA, Flynn L, Millar TF, DiMartino TM, Ryan SM, Stein MH. Reducing Anesthesia Use for Pediatric Magnetic Resonance Imaging: The Effects of a Patient- and Family-Centered Intervention on Image Quality, Health-care Costs, and Operational Efficiency. *J Radiol Nurs* [Internet]. 2019;38(1):21–7. Available from: <https://doi.org/10.1016/j.jradnu.2018.12.003>
46. De Bie HMA, Boersma M, Wattjes MP, Adriaanse S, Vermeulen RJ, Oostrom KJ, et al. Preparing children with a mock scanner training protocol results in high quality structural and functional MRI scans. *Eur J Pediatr*. 2010;169(9):1079–85.
47. Viggiano MP, Giganti F, Rossi A, Di Feo D, Vagnoli L, Calcagno G, et al. Impact of psychological interventions on reducing anxiety, fear and the need for sedation in children undergoing magnetic resonance imaging. *Pediatr Rep*. 2015;7(1):13–5.
48. Bjur KA, Payne ET, Nemergut ME, Hu D, Flick RP. Anesthetic-Related Neurotoxicity and Neuroimaging in Children: A Call for Conversation. *J Child Neurol* [Internet]. 2017;32(6):594–602. Available from: <http://www.ncbi.nlm.nih.gov/pubmed/28424007>  
<http://www.pubmedcentral.nih.gov/articlerender.fcgi?artid=PMC5407309>  
<http://journals.sagepub.com/doi/10.1177/0883073817691696>
49. Barton K, Nickerson JP, Higgins T, Williams RK. Pediatric anesthesia and neurotoxicity: what the radiologist needs to know. *Pediatr Radiol*. 2018;48(1):31–6.
50. Barnea-Goraly N, Weinzimer SA, Ruedy KJ, Mauras N, Beck RW, Marzelli MJ, et al. High success rates of sedation-free brain MRI scanning in young children

- using simple subject preparation protocols with and without a commercial mock scanner—the Diabetes Research in Children Network (DirecNet) experience. *Pediatr Radiol* [Internet]. 2014 Feb;44(2):181–6. Available from: <https://www.ncbi.nlm.nih.gov/pmc/articles/PMC3624763/pdf/nihms412728.pdf>
51. De Bie HMA, Boersma M, Wattjes MP, Adriaanse S, Vermeulen RJ, Oostrom KJ, et al. Preparing children with a mock scanner training protocol results in high quality structural and functional MRI scans. *Eur J Pediatr*. 2010;169(9):1079–85.
  52. Schulte-Uentrop L, Goepfert MS. Anaesthesia or sedation for MRI in children. *Curr Opin Anaesthesiol*. 2010;23(4):513–7.
  53. Kesseböhmer J. Can enhancing the MRI in-bore experience reduce the need for patient sedation? *Diagnostic Imaging Eur*. 2017;34–5.
  54. Sury M. Conscious sedation in children. *Contin Educ Anaesthesia, Crit Care Pain*. 2012;12(3):152–6.
  55. Reddy U, White MJ, Wilson SR. Anaesthesia for magnetic resonance imaging. *Contin Educ Anaesthesia, Crit Care Pain*. 2012;12(3):140–4.
  56. American College of Radiology. ACR – SAR – SPR Practice Parameter for the Performance of Magnetic Resonance (MR) Enterography. ACR – SAR – SPR Pract Param Perform Magn Reson Enterography by Am Coll Radiol [Internet]. 2015;1076(Revised 2008):1–10. Available from: <https://www.acr.org/-/media/ACR/Files/Practice-Parameters/MR-Enterog.pdf>
  57. Bettenworth D, Bokemeyer A, Baker M, Mao R, Parker CE, Nguyen T, et al. Assessment of Crohn’s disease-associated small bowel strictures and fibrosis on cross-sectional imaging: A systematic review. *Gut*. 2019;68(6):1115–26.
  58. Xiao YD, Paudel R, Liu J, Ma C, Zhang ZS, Zhou SK. MRI contrast agents: Classification and application (Review). *Int J Mol Med*. 2016;38(5):1319–26.
  59. Mohabir S, Pitcher RD, Perumal R, Goodier MDM. The efficacy of pineapple juice as a negative oral contrast agent in magnetic resonance cholangiopancreatography. *South African J Radiol*. 2020;24(1):1–6.
  60. Saini S, Colak E, Anthwal S, Vlachou PA, Raikhlina A, Kirpalani A. Comparison of 3% sorbitol vs psyllium fibre as oral contrast agents in MR enterography. *Br J Radiol*. 2014;87(1042).
  61. GE Healthcare. Discovery™ MR750w GEM.
  62. GE Healthcare. Optima™ MR450w [Internet]. 2010. Available from: <https://www.gehealthcare.co.uk/products/magnetic-resonance-imaging/1-5t/optima-mr450w-with-gem>
  63. Siemens. MAGNETOM Aera 1.5T. Siemens Healthcare GmbH. 2018. p. 20.
  64. Chavhan GB, Babyn PS, Jankharia BG, Cheng HLM, Shroff MM. Steady-state MR imaging sequences: Physics, classification, and clinical applications. *Radiographics*. 2008;28(4):1147–60.
  65. Baliyan V, Das CJ, Sharma R, Gupta AK. Diffusion weighted imaging: Technique

- and applications. *World J Radiol.* 2016;8(9):785.
66. Lee MH, Eutsler EP, Sheybani EF, Khanna G. Rapid non-contrast magnetic resonance imaging for post appendectomy intra-abdominal abscess in children. *Pediatr Radiol.* 2017;47(8):935–41.
  67. Shweta, Bajpai RC, Chaturvedi HK. Evaluation of inter-rater agreement and inter-rater reliability for observational data: An overview of concepts and methods. *J Indian Acad Appl Psychol.* 2015;41(Special Issue 3):20–7.
  68. Sim J, Wright CC. The kappa statistic in reliability studies: Use, interpretation, and sample size requirements. *Phys Ther.* 2005;85(3):257–68.
  69. Benjamin M. Davis, Glen F. Rall MJS. Pediatric neuro MRI: tricks to minimize sedation. *Physiol Behav.* 2017;176(1):139–48.
  70. Salerno S, Granata C, Trapenese M, Cannata V, Curione D, Rossi Espagnet MC, et al. Is MRI imaging in pediatric age totally safe? A critical reprisal. *Radiol Medica [Internet].* 2018;123(9):695–702. Available from: <https://doi.org/10.1007/s11547-018-0896-1>

## 8 Attachments

Attachment I: Authorization letter from the MRI Superintendent for the data collection.



Leicester, 8 October 2018

Dear Rajinder Sandhu,

I, Barbara Poiares, am carrying out a master dissertation entitled 'Challenges and optimization of Magnetic Resonance Imaging (MRI) in children', at the Lisbon Health School.

The request for MRI exams has grown in the paediatric population because of the non-use of ionizing radiation being less harmful for children. However, this type of examination requires that the child remains immobile throughout the exam, which in most cases is not possible. In these cases, the use of sedation or even general anaesthesia (GA) needs to be administered. This study has the purpose to help the reduction of MRI scans in children under GA as this procedure has variable complications and the need of a specialized team to monitor the patient during and after the exam.

Therefore, I would like to request your permission and collaboration to collect images from the Picture Archiving and Communication System (PACS) from your department on the Leicester Royal Infirmary to develop my project. This data will be anonymised, without any personal details or clinical history from the patients.

My sincere appreciation in anticipation of your assistance.

Regards,

Barbara Poiares

2<sup>nd</sup> year Student of the master Radiation Applied to Health Technologies

Lisbon Health School

received 12/10/18  
R Sandhu

ATTACHMENT II: Authorization email by the Clinical Audit Team regarding ethical concerns.

Dear Rajinder,

Thank you for submitting the attached project planner for the **Challenges and optimization of MRI Imaging in children audit**. I am pleased to confirm that the project has been approved and registered (Ref No. 9636) with you as the named supervisor.

The following are the main points included in UHL's guidance for project supervisors of clinical audits which we hope you'll be happy to follow: -

- that all 'interested parties' are consulted before the project commences (data should not be gathered about clinicians' practice for clinical audit purposes without their prior knowledge) and due consideration has been given to the involvement of patients
- that no healthcare professional or patient can be identified directly, or indirectly, from a report without their explicit approval
- that quarterly updates on progress with the project are sent to the clinical audit team and specialty audit lead(s)
- that audit findings are presented to an appropriate meeting within your speciality/CMG and beyond, according to the nature of the project
- that a clinical audit summary form detailing the action plan is completed in a timely manner and sent to speciality audit lead for sign-off. *(A 1st draft has been created from the information provided in the planner and is attached).*
- that any audit findings are assessed for associated risk and that these are included in the summary form and, if necessary, on the risk register.
- that any external publication of audit results receives the prior approval of the speciality audit lead / Head of Service.

For further details please give me a call or refer to the audit policy ([link](#)). If there are any anticipated problems with any of the above please let me know.

Please let me know if the clinical audit team can be of any further assistance.

Kind Regards,

Rizwan Patel

Project Support Officer

Clinical Audit Team

University Hospitals of Leicester NHS Trust

ATTACHMENT III: Email from the Ethic Board of ESTESL approving the project.

## **RESPOSTA CE - Challenges of magnetic Resonance Imaging in the Child: effects of consciousness induction decay in Entero-MR**

**Conselho de Ética da ESTeSL** <conselhodeetica@estesl.ipl.pt> 21 de maio de 2020 às 14:31

Para: Margarida Ribeiro <margarida.ribeiro@estesl.ipl.pt>

Cc: bas.poiares@gmail.com

**REFERÊNCIA INTERNA DO PROJETO: CE-ESTeSL-Nº.14-2020- Bárbara Alexandra da Silva Poiares**

**TÍTULO DO DE PROJETO:** Challenges of magnetic Resonance Imaging in the Child: effects of consciousness induction decay in Entero-MR

**TIPO DE PROJETO/ESTUDO:** do ramo de Ressonância Magnética do Mestrado em Radiações Aplicadas às Tecnologias da Saúde

**INVESTIGADOR/A PRINCIPAL:** Bárbara Alexandra da Silva Poiares

**ORIENTADOR/ES:** Maria Margarida do Carmo Pinto Ribeiro

**INSTITUIÇÃO PROMOTORA:** Escola Superior de Tecnologia da Saúde de Lisboa

**INSTITUIÇÃO(ÕES) ENVOLVIDAS:** Escola Superior de Tecnologias da Saúde de Lisboa; Leicester Royal Infirmary  
- University Hospitals of Leicester

**EQUIPA:** -

**RECEBIDO:** 11 março 2020

**RESPOSTA CE:**

Exm<sup>a</sup>. Senhora Prof<sup>a</sup>. Doutora Maria Margarida do Carmo Pinto Ribeiro

Exm<sup>a</sup>. Senhora Dr<sup>a</sup>. Bárbara Alexandra da Silva Poiares, estudante de Mestrado

Após análise do projeto supracitado o Conselho de Ética (CE) da Escola Superior de Tecnologia da Saúde de Lisboa (ESTeSL) considerou que:

- 1) tratar-se de um estudo retrospectivo, onde o consentimento informado dos pacientes/familiares foi obtido na devida altura e autorizado pela instituição onde as imagens de ressonância magnética foram recolhidas (Leicester Royal Infirmary).
- 2) as imagens foram devidamente anonimizadas antes do seu uso neste estudo,

Face ao exposto o Conselho de Ética (CE) da Escola Superior de Tecnologia da Saúde de Lisboa (ESTeSL) considerou por unanimidade que o estudo não levanta questões do ponto de vista ético tendo aprovado por unanimidade a emissão de parecer favorável.

Lembramos ainda que todos os estudos que envolvem a autorização dos participantes e a recolha de amostras e dados anonimizados e/ou codificados têm de cumprir com o estabelecido no Regulamento Geral sobre a Proteção de Dados de 27 de abril de 2016.

Por último, solicita-se também que, ao abrigo do artº 19 da Lei 21/2014 de 16 de abril e do disposto no nº23 da atual versão da Declaração de Helsínquia, dê igualmente conhecimento ao Conselho de Ética da ESTeSL do relatório final com as conclusões do estudo, de eventuais alterações ao protocolo de investigação e demais informações tidas por relevantes.

Aproveitamos ainda para desejar o maior sucesso no desenvolvimento deste trabalho.

Com os melhores cumprimentos,

**Profª. Coordenadora Helena Soares**

**Presidente do Conselho de Ética da ESTeSL**


Escola Superior de Tecnologia da Saúde de Lisboa

Av. D. João II, lote 4.69.01, 1990-096 Lisboa

Tel. 218 980 447; Fax. 218 980 460

ATTACHMENT IV: MRI safety questionnaire of Cross-Sectional Department at University Hospital of Leicester (UHL).

**MRI SAFETY QUESTIONNAIRE**

University Hospitals of Leicester 

Name..... Date of Birth.....

Address.....

Height.....Weight.....

|   | YES | NO |
|---|-----|----|
| Do you or have you <b>ever</b> had a pacemaker, heart valve or heart stent?<br>Details.....   |     |    |
| Have you <b>ever</b> had an operation on your head, eyes or ears?<br>Details.....   |     |    |
| Have you <b>ever</b> had any operations elsewhere in the body?<br>Details.....  |     |    |
| Do you have a hydrocephalus shunt?<br>Is it programmable?.....  |     |    |
| Do you have any implants? (eg. joint replacement, clips, stents, coils,<br>electrical, GI video capsules, magnetic, cochlear)<br>Details.....   |     |    |
| Have you ever had any metal fragments, splinters, shrapnel, or gunshot<br>wounds anywhere in the body especially your eye?<br>Do you have metal dentures in or are you wearing a hearing aid? |     |    |
| Are you wearing any drug patches on your skin, any tattoos or any body<br>piercing in?<br>Do you suffer from fits?  |     |    |
| Do you suffer from diabetes?  |     |    |
| Do you suffer from asthma or have any allergies?  |     |    |
| Do you have any kidney problems?  |     |    |
| Are you, or is there any possibility that you may be pregnant, or are you breast<br>feeding?  |     |    |

Please remove all loose metal objects including your watch, money, credit cards, keys, all jewellery, hair clips, wigs or hair pieces, heavy eye make-up, coloured contact lenses and metal on clothing.

The MRI procedure has been explained to me. I understand that the Doctor supervising my study may wish me to have an injection of an intravenous contrast.

I consent to the MRI examination and contrast injection if required.

I confirm that I have answered all of the above questions correctly.

Patient / Parent / Guardian / Volunteer

Signature.....Date .....

I confirm that all metallic items, e.g. ECG electrodes, external pacing wires, have been removed from the patient, and that there are no visible sutures or clips that may be unsafe for MRI scanning.

Radiographer / Assistant Practitioner ..... Date .....

ATTACHMENT V: Consent form for general anaesthetic procedures of Imagology Department at University Hospital of Leicester (UHL).

**WHS**

PLEASE PRESS HARD AND USE A BALL POINT PEN

**Patient details (or pre-printed label - both copies)**

Patient's surname/family name \_\_\_\_\_

Patient's first names \_\_\_\_\_

Date of birth \_\_\_\_\_

Responsible health professional \_\_\_\_\_

Job Title \_\_\_\_\_

NHS number (or other identifier) \_\_\_\_\_

Male  Female

**Special requirements**

eg other language / other communication method \_\_\_\_\_

**Name of proposed procedure or course of treatment**  
(include brief explanation if medical term not clear)

\_\_\_\_\_

\_\_\_\_\_

\_\_\_\_\_

**Statement of health professional**  
(to be filled in by health professional with appropriate knowledge of proposed procedure, as specified in consent policy)  
I have explained the procedure to the patient. In particular, I have explained:  
The intended benefits \_\_\_\_\_

Significant, unavoidable or frequently occurring risks \_\_\_\_\_

Fix Label Here

Any extra procedures which may become necessary during the procedure  
 blood transfusion  
 other procedure (please specify) \_\_\_\_\_

I have also discussed what the procedure is likely to involve, the benefits and risks of any available alternative treatments (including no treatment) and any particular concerns of this patient.  
 The following leaflet/trape has been provided

This procedure will involve:  
 general and/or regional anaesthesia  
 local anaesthesia  
 sedation

Signed: \_\_\_\_\_ Date \_\_\_\_\_  
 Name (PRINT) \_\_\_\_\_ Job Title \_\_\_\_\_

**Contact details** (if patient wishes to discuss options later)  
**Statement of interpreter** (where appropriate)  
 I have interpreted the information above to the patient to the best of my ability and in a way in which I believe s/he can understand.  
 Signed: \_\_\_\_\_ Date \_\_\_\_\_  
 Name (PRINT) \_\_\_\_\_

**University Hospitals of Leicester NHS Trust**  
**CONSENT FORM 1**

**PATIENT AGREEMENT TO INVESTIGATION OR TREATMENT**

**Statement of patient**

Please read this form carefully. You will be given a copy of this consent form which describes the benefits and risks of the proposed treatment. If you have any further questions, do ask - we are here to help you. You have the right to change your mind at any time, including after you have signed this form.

I agree to the procedure or course of treatment described on this form.

I understand that you cannot give me a guarantee that a particular person will perform the procedure. The person will, however, have appropriate experience.

I understand that I will have the opportunity to discuss the details of anaesthesia with an anaesthetist before the procedure, unless the urgency of my situation prevents this.  
(This only applies to patients having general or regional anaesthesia.)

I understand that any procedure in addition to those described on this form will only be carried out if it is necessary to save my life or to prevent serious harm to my health.

I have been told about additional procedures which may become necessary during my treatment. I have listed below any procedures which I do not wish to be carried out without further discussion.

\_\_\_\_\_

\_\_\_\_\_

\_\_\_\_\_

Patient's signature \_\_\_\_\_ Date \_\_\_\_\_  
 Name (PRINT) \_\_\_\_\_

A witness should sign below if the patient is unable to sign but has indicated his or her consent.  
 Young people/children may also like a parent to sign here (see notes).

Signed: \_\_\_\_\_ Date \_\_\_\_\_  
 Name (PRINT) \_\_\_\_\_

**Confirmation of consent**  
 (to be completed by a health professional when the patient is admitted for the procedure, if the patient has signed the form in advance)

On behalf of the team treating the patient,  
 I have confirmed with the patient that s/he has no further questions and wishes the procedure to go ahead.

Signed: \_\_\_\_\_ Date \_\_\_\_\_  
 Name (PRINT) \_\_\_\_\_ Job title \_\_\_\_\_

**Important notes: (tick if applicable)**

See also advance directive/living will (eg Jehovah's Witness form)

Patient has withdrawn consent (ask patient to sign / date here) \_\_\_\_\_

DISTRIBUTION: WHITE TO PATIENT'S NOTES, YELLOW TO PATIENT.

W10

ATTACHMENT VI: Example of the questionnaire performed by the assessors with a *Likert* scale of three classifications.

|    | PATIENT HOSPITAL NUMBER | EXAM DATE | SUB-OPTIMAL | OPTIMAL | EXCELENT FOR DIAGNOSTIC | COMMENTS |
|----|-------------------------|-----------|-------------|---------|-------------------------|----------|
| 1  |                         | oct/18    |             |         |                         |          |
| 2  |                         | aug/18    |             |         |                         |          |
| 3  |                         | jul/18    |             |         |                         |          |
| 4  |                         | jun/18    |             |         |                         |          |
| 5  |                         | may/18    |             |         |                         |          |
| 6  |                         | feb/19    |             |         |                         |          |
| 7  |                         | may/18    |             |         |                         |          |
| 8  |                         | may/18    |             |         |                         |          |
| 9  |                         | may/18    |             |         |                         |          |
| 10 |                         | may/18    |             |         |                         |          |
| 11 |                         | jun/18    |             |         |                         |          |
| 12 |                         | apr/18    |             |         |                         |          |
| 13 |                         | apr/18    |             |         |                         |          |
| 14 |                         | apr/18    |             |         |                         |          |
| 15 |                         | apr/18    |             |         |                         |          |
| 16 |                         | mar/18    |             |         |                         |          |
| 17 |                         | feb/18    |             |         |                         |          |
| 18 |                         | may/17    |             |         |                         |          |
| 19 |                         | jan/18    |             |         |                         |          |
| 20 |                         | dec/17    |             |         |                         |          |
| 21 |                         | dec/17    |             |         |                         |          |
| 22 |                         | dec/17    |             |         |                         |          |
| 23 |                         | nov/17    |             |         |                         |          |
| 24 |                         | jul/15    |             |         |                         |          |
| 25 |                         | sept/17   |             |         |                         |          |
| 26 |                         | aug/17    |             |         |                         |          |
| 27 |                         | jul/17    |             |         |                         |          |
| 28 |                         | jul/17    |             |         |                         |          |
| 29 |                         | jun/17    |             |         |                         |          |
| 30 |                         | oct/16    |             |         |                         |          |
| 31 |                         | jun/17    |             |         |                         |          |
| 32 |                         | jun/17    |             |         |                         |          |
| 33 |                         | jun/17    |             |         |                         |          |
| 34 |                         | may/17    |             |         |                         |          |
| 35 |                         | may/17    |             |         |                         |          |
| 36 |                         | apr/17    |             |         |                         |          |
| 37 |                         | mar/17    |             |         |                         |          |
| 38 |                         | apr/14    |             |         |                         |          |
| 39 |                         | mar/17    |             |         |                         |          |
| 40 |                         | jan/17    |             |         |                         |          |

|    |  |        |  |  |  |  |
|----|--|--------|--|--|--|--|
| 41 |  | jan/17 |  |  |  |  |
| 42 |  | jan/17 |  |  |  |  |
| 43 |  | dec/16 |  |  |  |  |
| 44 |  | dec/16 |  |  |  |  |
| 45 |  | dec/15 |  |  |  |  |
| 46 |  | dec/16 |  |  |  |  |
| 47 |  | dec/16 |  |  |  |  |
| 48 |  | oct/16 |  |  |  |  |
| 49 |  | oct/16 |  |  |  |  |
| 50 |  | oct/16 |  |  |  |  |
| 51 |  | aug/16 |  |  |  |  |
| 52 |  | aug/16 |  |  |  |  |
| 53 |  | aug/16 |  |  |  |  |
| 54 |  | aug/16 |  |  |  |  |
| 55 |  | nov/15 |  |  |  |  |
| 56 |  | jul/16 |  |  |  |  |
| 57 |  | jun/16 |  |  |  |  |
| 58 |  | jun/16 |  |  |  |  |
| 59 |  | may/16 |  |  |  |  |
| 60 |  | feb/14 |  |  |  |  |
| 61 |  | may/16 |  |  |  |  |
| 62 |  | may/16 |  |  |  |  |
| 63 |  | apr/16 |  |  |  |  |
| 64 |  | apr/16 |  |  |  |  |
| 65 |  | mar/16 |  |  |  |  |
| 66 |  | feb/16 |  |  |  |  |
| 67 |  | jan/16 |  |  |  |  |
| 68 |  | dec/14 |  |  |  |  |
| 69 |  | jan/16 |  |  |  |  |
| 70 |  | jan/16 |  |  |  |  |
| 71 |  | jan/16 |  |  |  |  |
| 72 |  | nov/15 |  |  |  |  |
| 73 |  | feb/15 |  |  |  |  |

ATTACHMENT VII: Checklist of good practices and strategies for paediatric MRI exams.

|   |   |
|---|---|
| Preparation for the MRI scan                    | <p>Mock scans;</p> <p>Teaching tools (e.g. manufactures apps, video tutorials);</p> <p>Letter with a link for a video tutorial.</p>   |
| At home (parents/guardians)                     | <p>Familiarize with the environment, sounds, while teaching them skills (such as breathing, relaxation, or distraction);</p> <p>Testing how long they can keep still (e.g. 10 seconds);</p> <p>Contact the parents to monitor the preceding process and clarify any doubts;</p> <p>Preparation should start a week before the exam.</p>   |
| Arriving at the department/ in the waiting area | <p>Dedicated reception area with child-friendly decoration;</p> <p>Mock scans/Toys;</p> <p>Play specialists.</p>  |
| Preparation room (activities)                   | <p>Conversation with the child:</p> <ul style="list-style-type: none"> <li>- try to understand their hobbies and activities, making them comfortable and able to abstract from the scan;</li> </ul> <p>Getting the parents involve in all the process;</p> <p>Give the children the driver of the process;</p> <p>Previous simulation learning the children to insert your body below a chair in replace of the bore.</p> |
| MRI room  | <p>Immobilization devices;</p> <p>Distraction (adapt scanners, with e.g. radio/music, video goggles);</p> <p>Parents holding their hands.</p>   |
| Scan acquisition (radiographer)                 | <p>Adapt protocol per age;</p>  |

|                       |  |
|-----------------------|--|
|                       | <p>Time per sequence – reduce time sequences</p> <p>Speaking with the child;</p> <p>Noise reduction sequences;</p> <p>Toys to take inside with them;</p> <p>Younger children – pacifiers orthodontic.</p>  |
| <p>After the scan</p> | <p>Feedback, understand if it was a good experience for the child was – what can be improved;</p> <p>Younger children's – stickers, adapted certificates depending on the age;</p> <p>Memory panel – after the scan, they can leave their mark, placing their hand with ink in a big panel.</p> <p>An audit should be made every year to understand what can be improved based on information recovered through parents/guardians and topics from well-successful experiences.</p> |