



Associação Portuguesa de
Osteogénese Imperfeita



ESCOLA SUPERIOR DE
TECNOLOGIA DA SAÚDE
DE LISBOA

INSTITUTO POLITÉCNICO DE LISBOA

CENTRO HOSPITALAR
LISBOA NORTE, EPE



HSM



HPV

See, Hear, Smile!

Topical Meeting on Osteogenesis Imperfecta

TALLINK HOTEL - RIGA - LATVIA

14TH - 15TH OF JUNE 2019

Ocular changes in OI in a Portuguese population

Rafael Barão, MD



Conflicts of interest

I, Rafael Barão, DO NOT have a financial interest/arrangement or affiliation with one or more organizations which could be perceived as a real or apparent conflict of interest in the context of the subject of this presentation

Background

- OI can cause several ocular manifestations
- **The most common (and noticeable) is the bluish coloration of the sclerae (+ type I)^{1,2}**
- Other common manifestations include
 - **Reduced corneal thickness^{2,3, 4} and rigidity⁴**
 - High refractive errors⁵
 - **Keratoconus^{6,7}**
 - Glaucoma (higher incidence *de per se* or higher risk?)^{2,8, 9, 10, 11}
- Less common: scleral rupture¹², retinal hemorrhages¹³, CNV¹⁴, among others

1. Sillence *et. al.* 1993
2. Hald *et al.* 2018
3. Pedersen *et. al.* 1984
4. Lagrou *et. al.* 2018
5. Chau *et. al.* in *Osteogenesis Imperfecta*, 2014
6. Beckh *et. Al.* 1995
7. Zeri *et. al.* 2018
8. Congdon *et. al.* 2006
9. Rosbach *et. al.* 2011
10. Wallace *et. al.* 2014
11. Pirouzian *et. al.* 2007
12. Mauri *et. al.* 2016
13. Ganesh *et. al.* 2004



Objectives

- Assess and explore the ocular features of OI patients in an adult Portuguese population
- Exploratory analysis of relationships between OI types and ocular phenotypes
- Exploratory analysis of relationships between several variables



CENTRO HOSPITALAR
LISBOA NORTE, EPE



Study design and setting

- An ongoing cross-sectional study on the ocular features in OI patients
- Protocol involves coordinated visitations to several departments
 - Cardiology, Genetics, Rheumatology, Stomatology and Ophthalmology



CENTRO HOSPITALAR
LISBOA NORTE, EPE

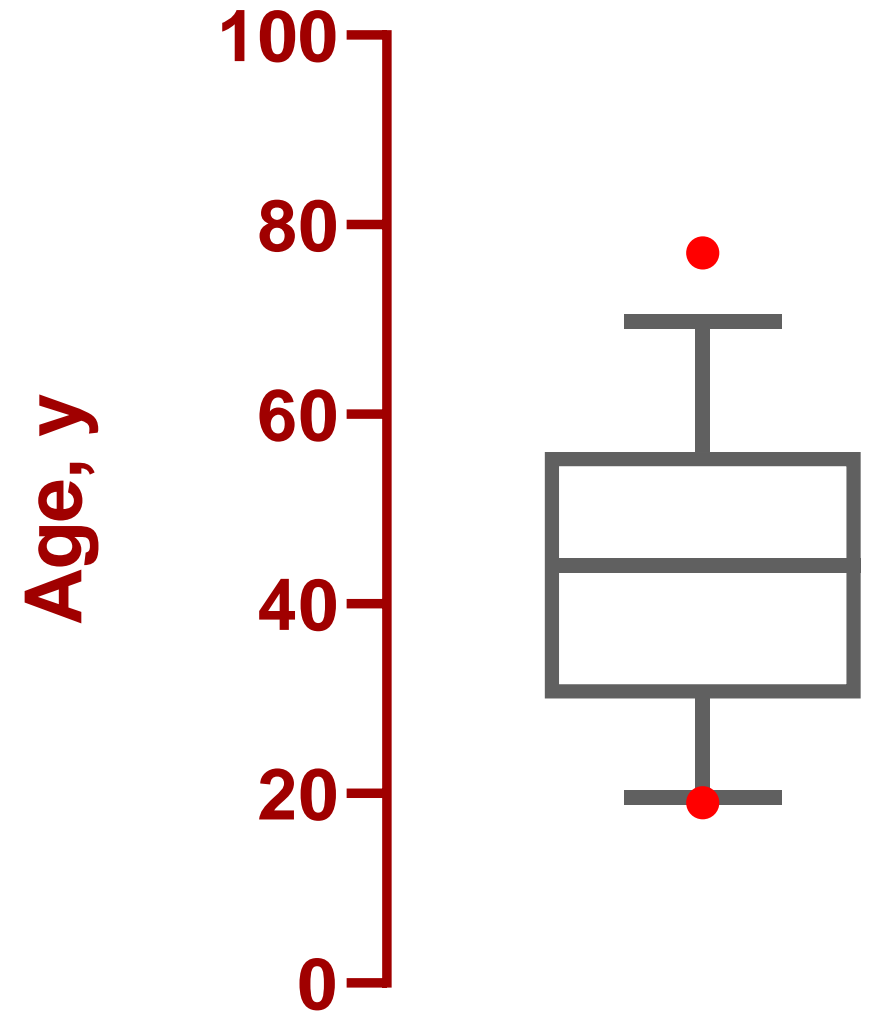


Methods

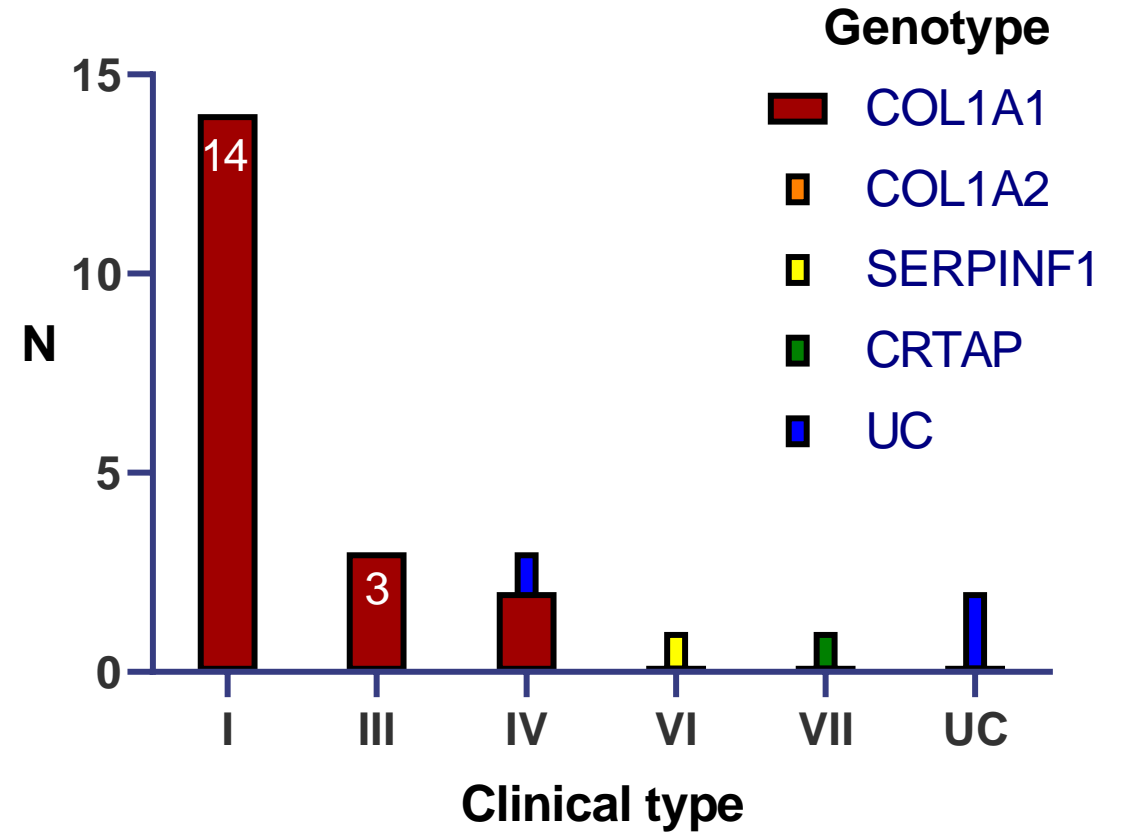
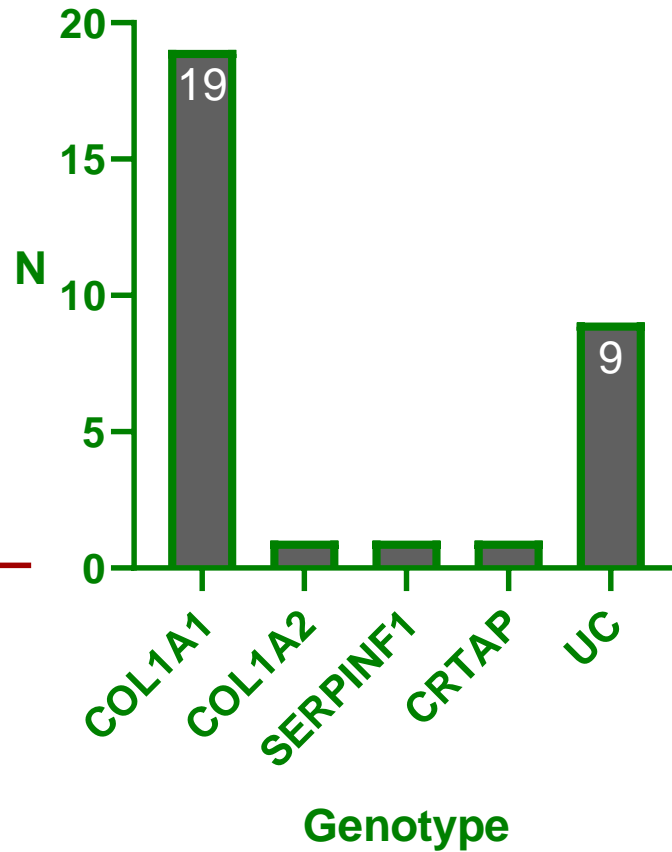
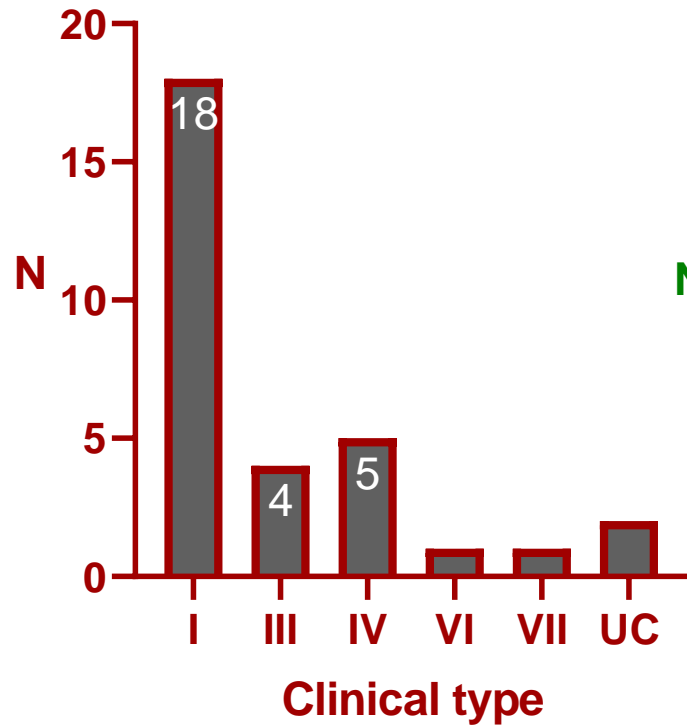
- **All patients underwent complete ophthalmological exam and extensive testing**
 - BCVA, ocular motility and alignment testing
 - Slit-lamp biomicroscopy and fundus observation
 - Automated refractometry
 - Tonometry (GAT)
 - Corneal tomography (Pentacam[®] HR)
 - Non-mydratic retinography

Sample

- 31 adult Portuguese patients have enrolled
 - 24 ♀, 7 ♂
 - Mean age: $43 \pm 16y$
 - Height 146 ± 19 cm and weight 57 ± 16 kg

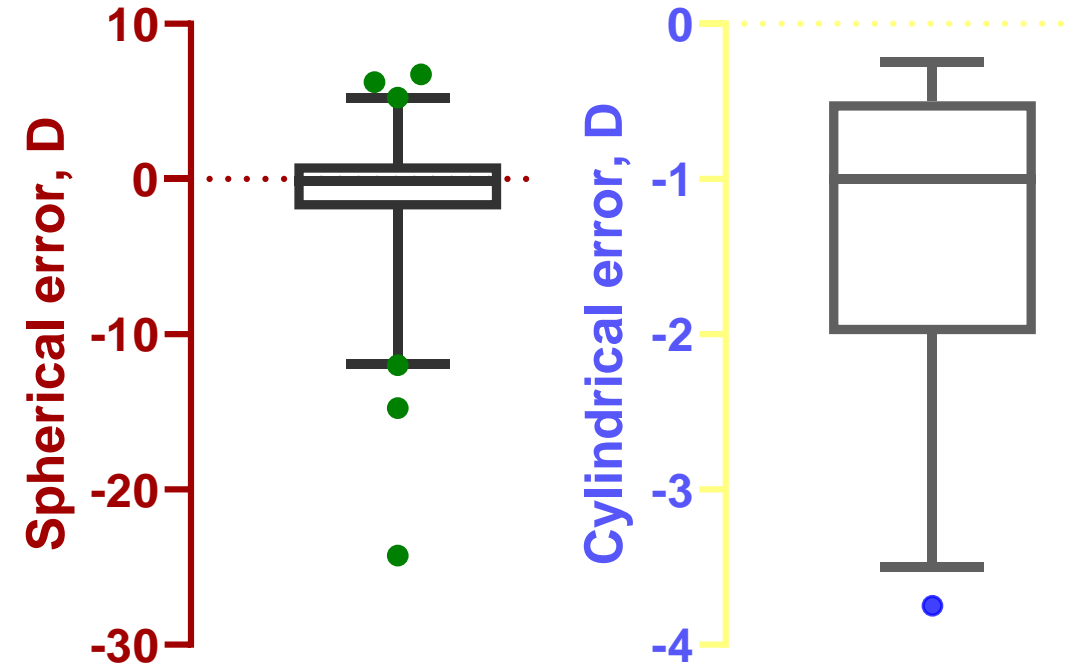


OI clinical type and genotype



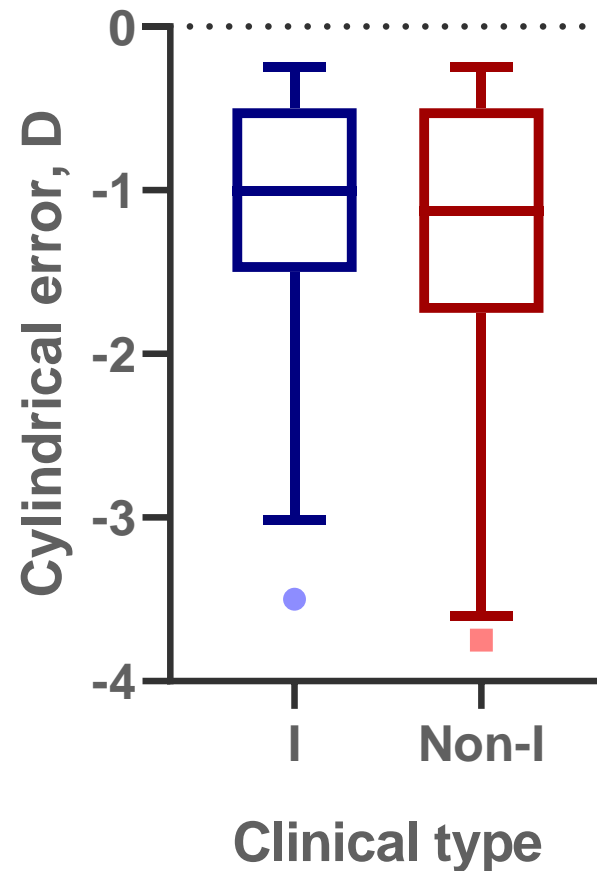
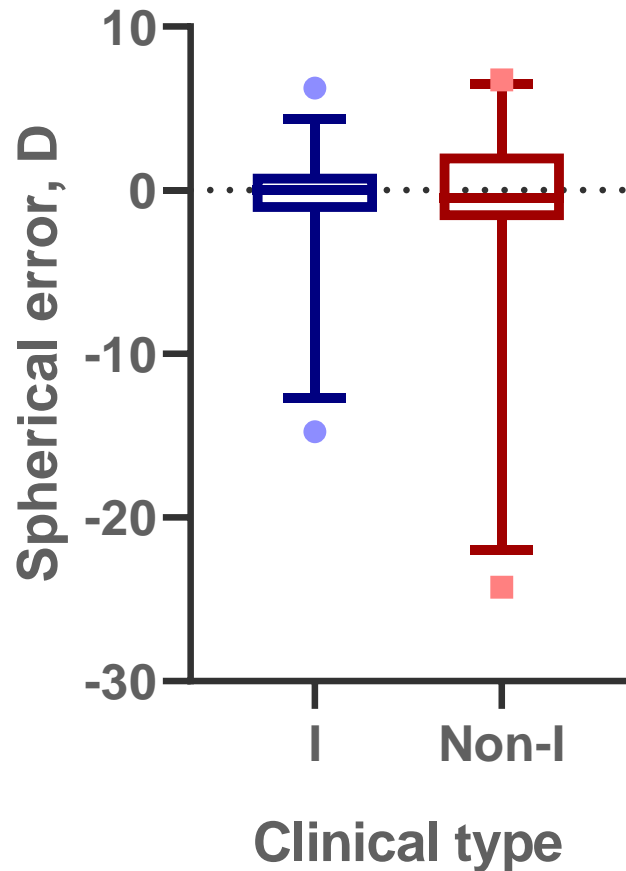
Visual acuity and refractive errors

- Mean **BCVA $0,09 \pm 0,2$ logMAR** (similar OU)
- Mean Sph $-1,3 \pm 5,2$ D, Cyl $-1,3 \pm 0,9$ D
 - **7 patients w/ high grade refractive errors**
 - High myopia (range $-6,5$ to -24 D): 8 eyes
 - High hyperopia (range $5,25$ to $6,75$ D): 3 eyes
 - Cyl: 52% WTR, 25% ATR, 23% Obl
- BCVA correlated with Sph error ($r = -0,3$; $p = 0,01$)



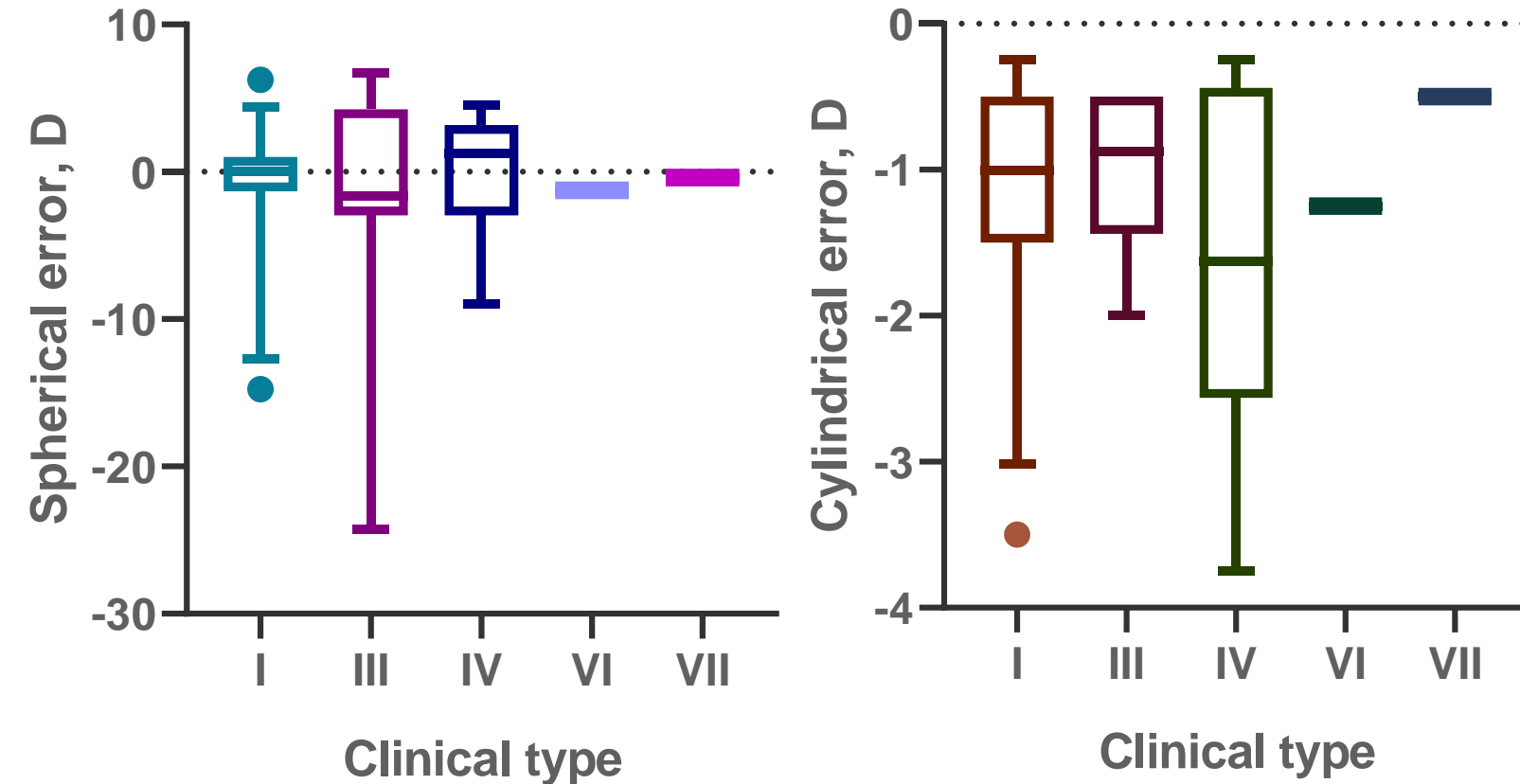
Visual acuity and refractive errors

- **No significant difference** in BCVA or refractive errors **between OI clinical or genetic types**



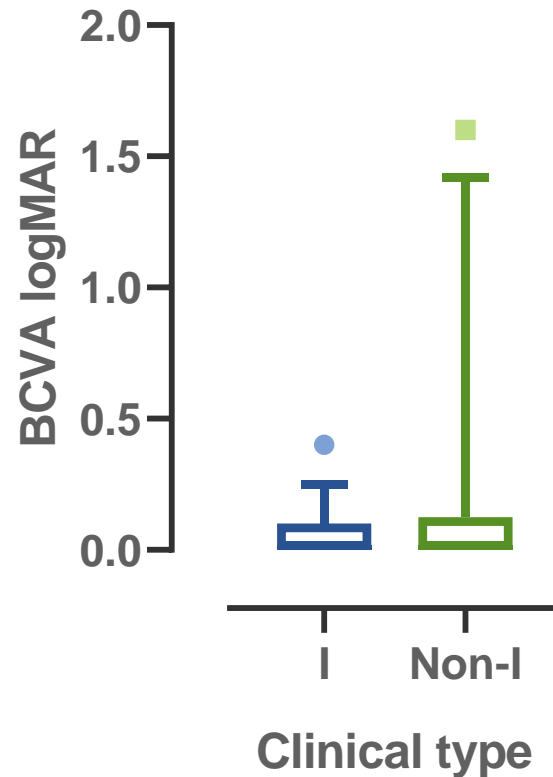
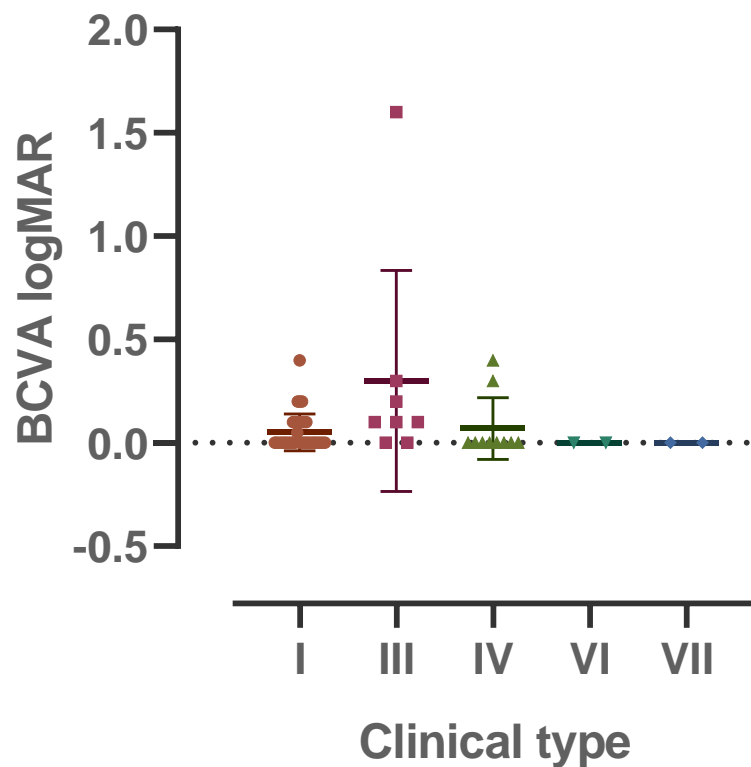
Visual acuity and refractive errors

- **No significant difference** in BCVA or refractive errors **between OI clinical or genetic types**



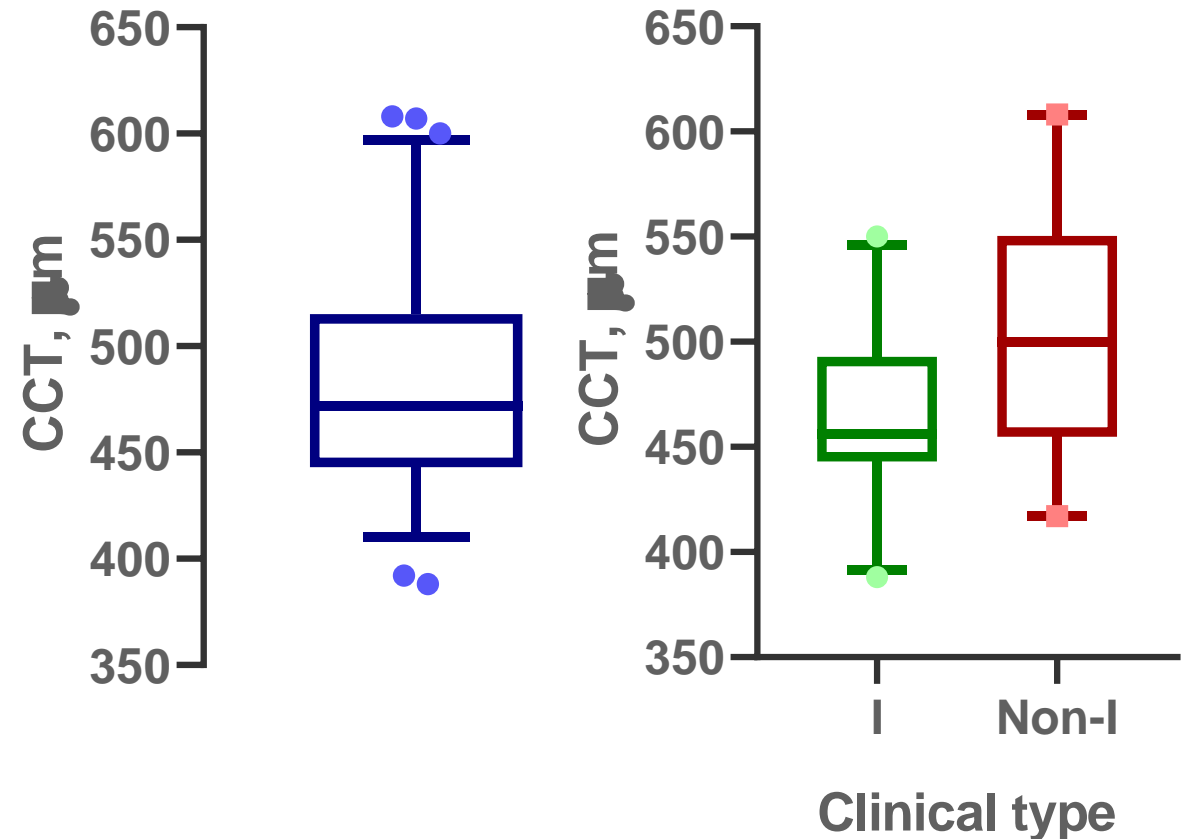
Visual acuity and refractive errors

- **No significant difference** in BCVA or refractive errors **between OI clinical or genetic types**



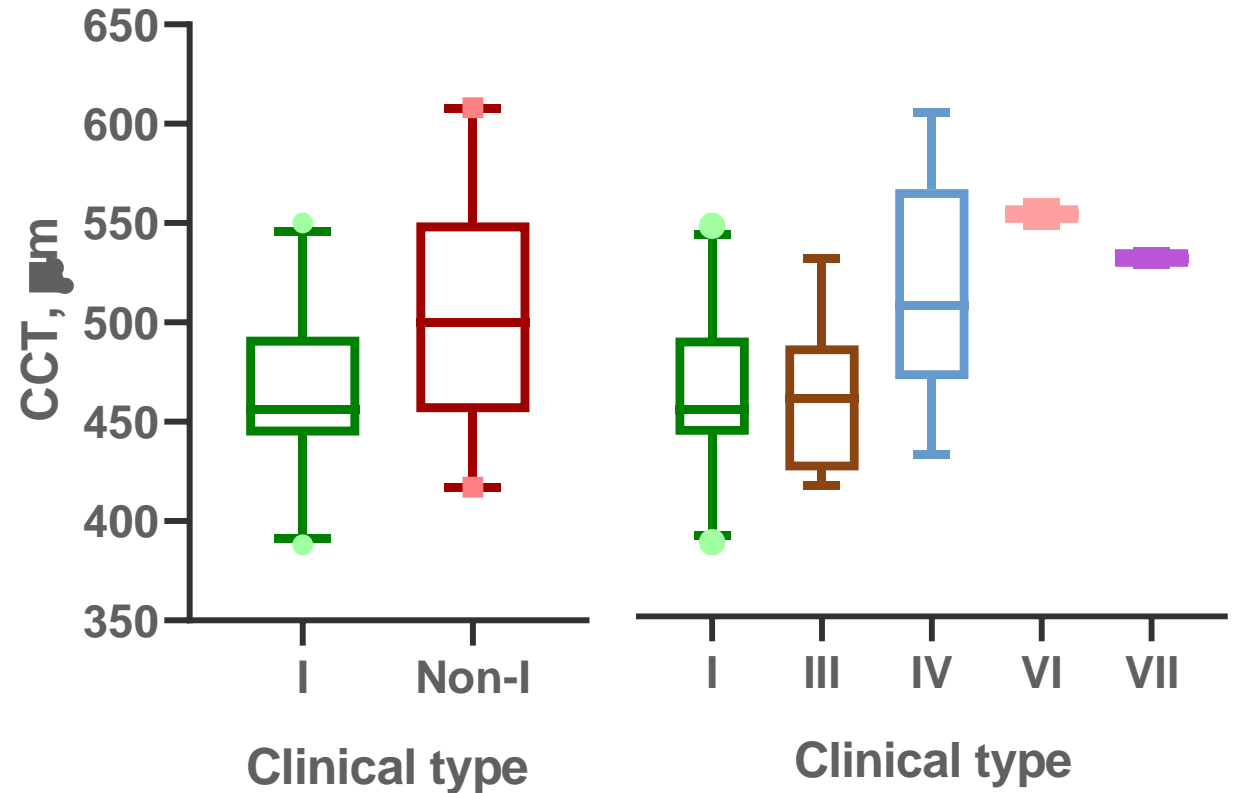
Corneal thickness

- Avg CCT was **481 ± 54 μm** (similar OU)
 - **Significantly reduced** vs. reference range¹
($p < 0,001$)
 - **Significantly different between OI type I and non-type I** ($p = 0,01$)
 - **Types I vs. IV** ($p = 0,026$)
 - Types I vs. III ($p > 0,05$)
- **77% of patients had thin corneas**
 - 2 patients had thick corneas (avg 599 μm)
 - 1 **type IV** and 1 thus far unclassified
 - 5 patients had normal CCT



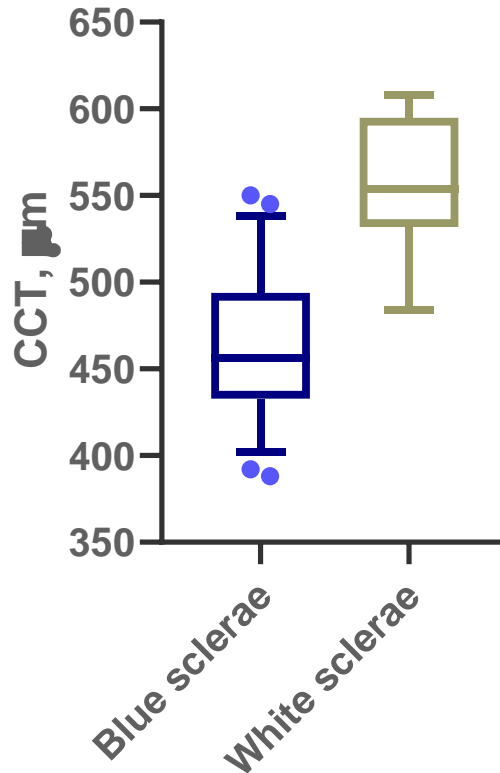
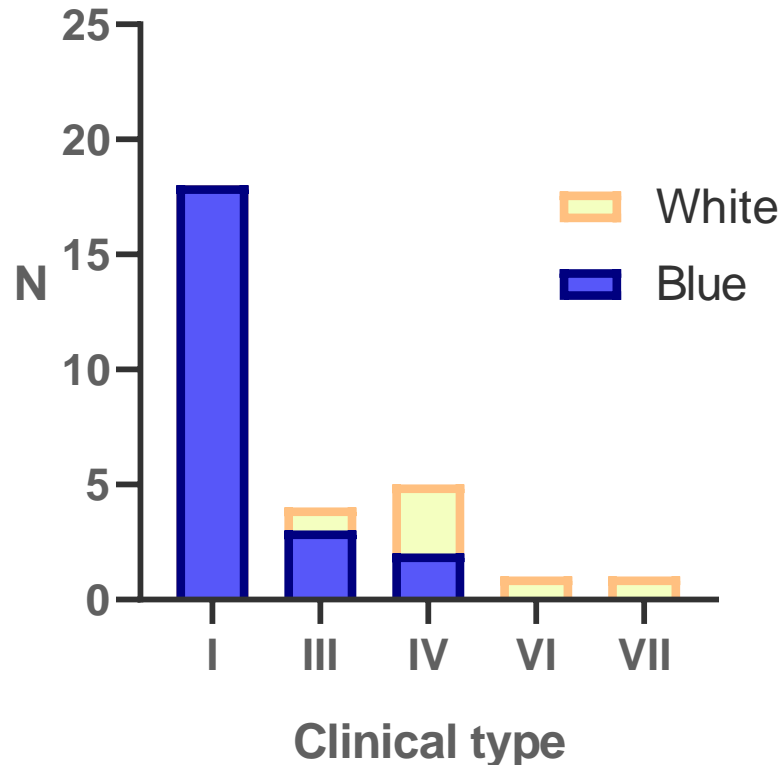
Corneal thickness

- Avg CCT was **481 ± 54 μm** (similar OU)
 - **Significantly reduced** vs. reference range¹ (p < 0,001)
 - **Significantly different between OI type I and non-type I** (p = 0,01)
 - **Types I vs. IV** (p = 0,026)
 - Types I vs. III (p > 0,05)
- **77% of patients had thin corneas**
 - 2 patients had thick corneas (avg 599 μm)
 - 1 **type IV** and 1 thus far unclassified
 - 5 patients had normal CCT



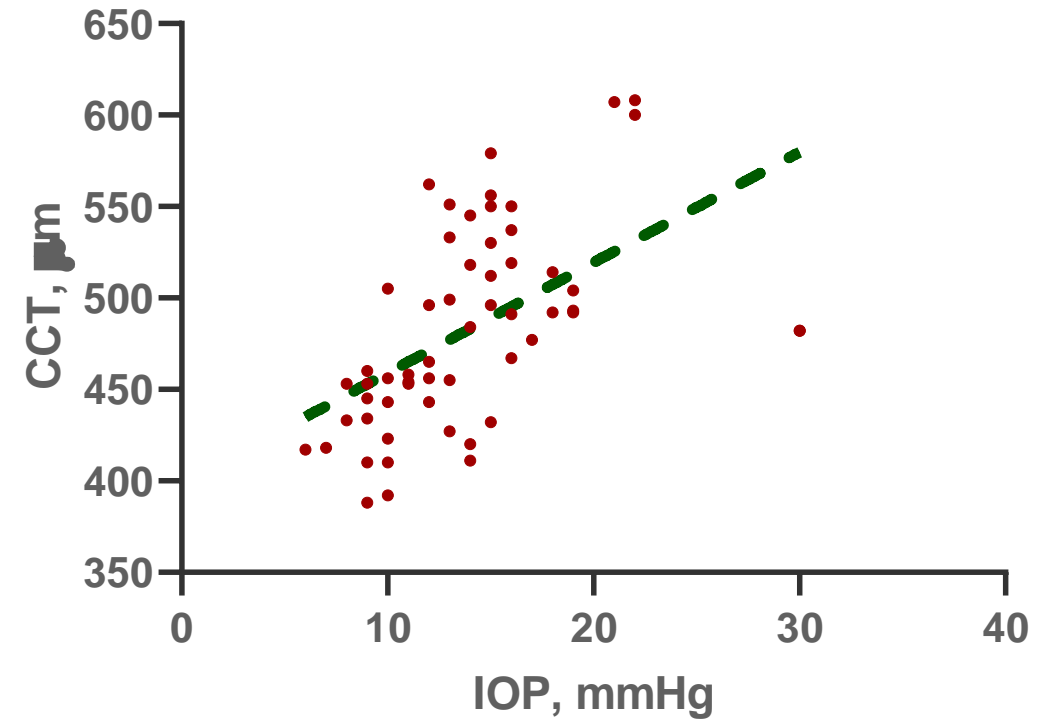
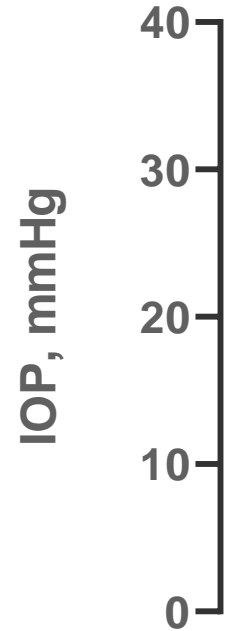
Sclerae

- **80%** of patients had some form of (dis)coloration of the sclerae
- **CCT was significantly lower in patients with blue sclerae** ($p < 0,001$)



Intraocular pressure

- Mean IOP $13,8 \pm 4,8$ mmHg
- **IOP correlated with CCT**
($p < 0,001$)
 - **Blue vs. white sclerae**
 $13,2 \pm 4,9$ vs. $16,3 \pm 3,4$ mmHg
($p = 0,03$)
- **Did not differ** significantly
between **OI types**



Intraocular pressure

- Mean IOP $13,8 \pm 4,8$ mmHg

- IOP correlated with CCT

($p < 0,001$)

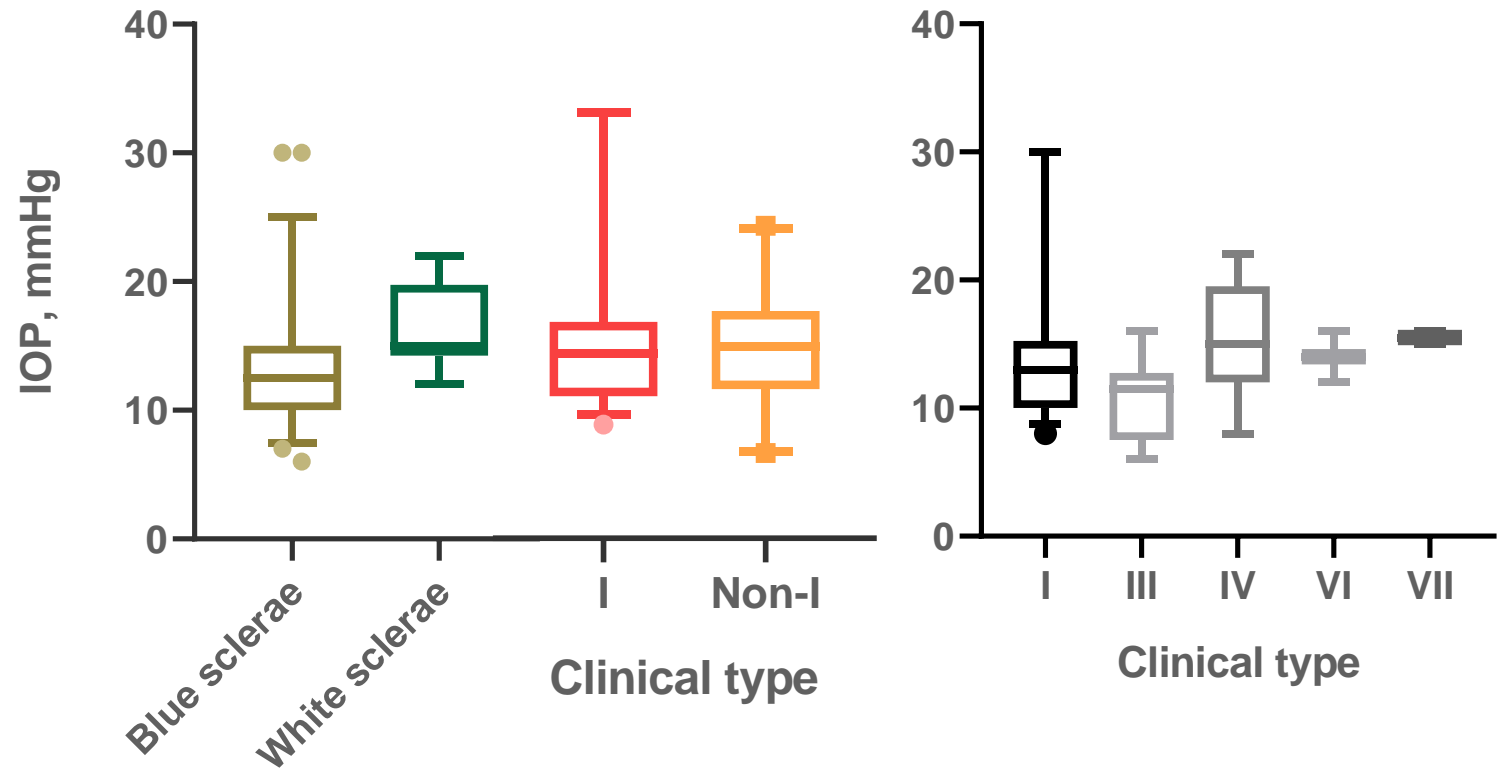
- Blue vs. white sclerae

$13,2 \pm 4,9$ vs. $16,3 \pm 3,4$ mmHg

($p = 0,03$)

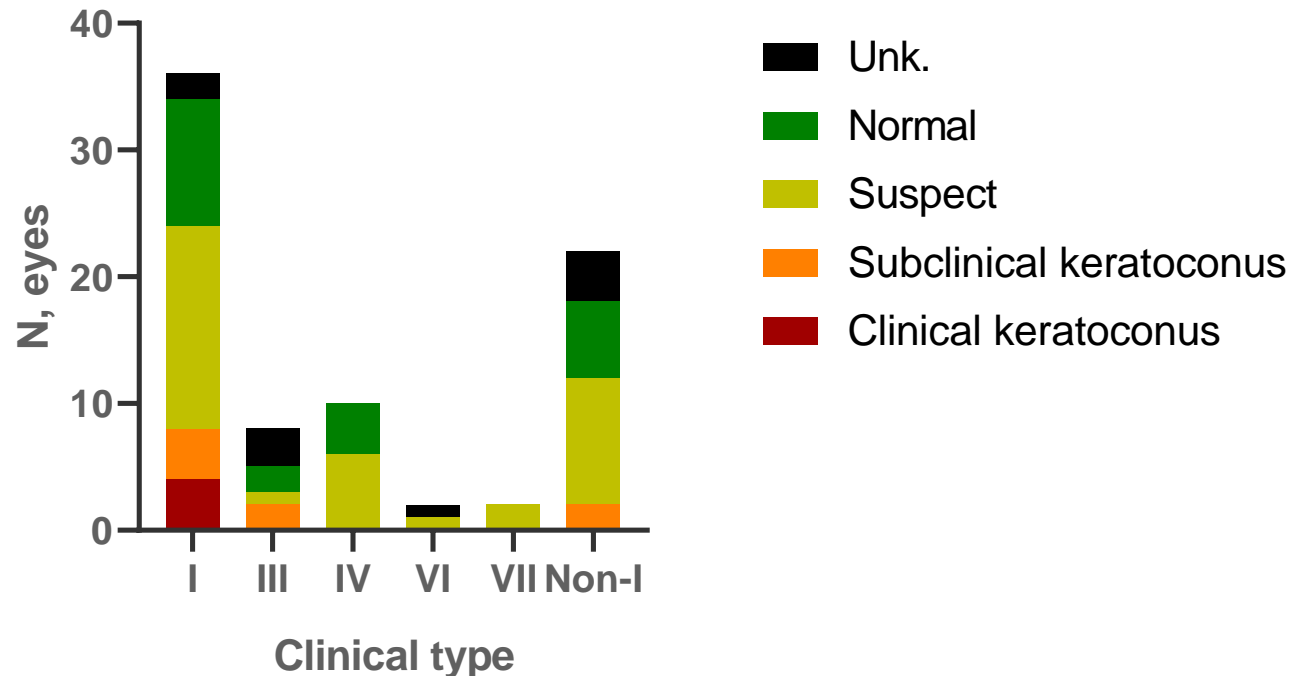
- Did not differ significantly

between OI types

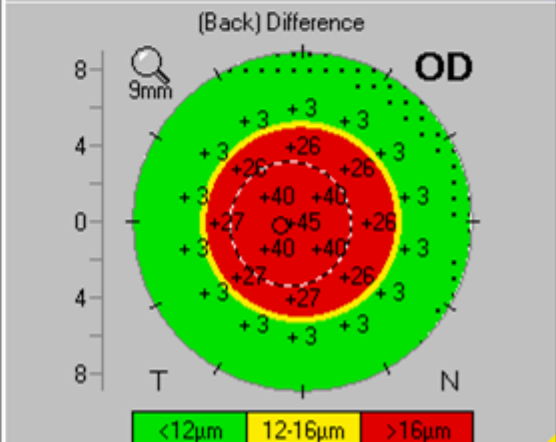
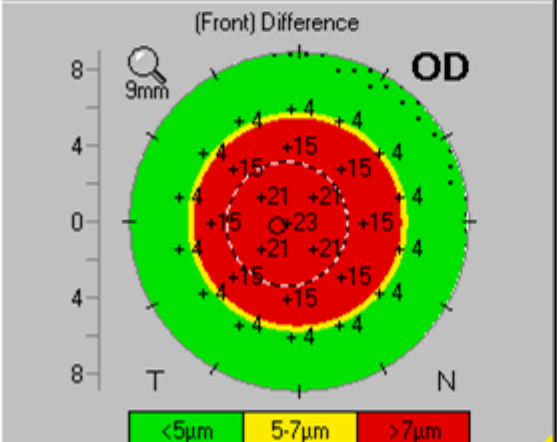
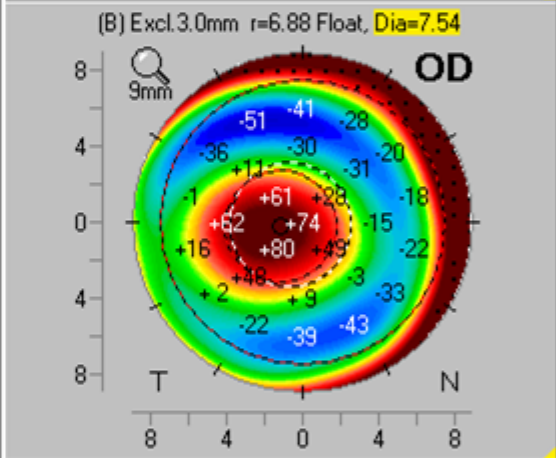
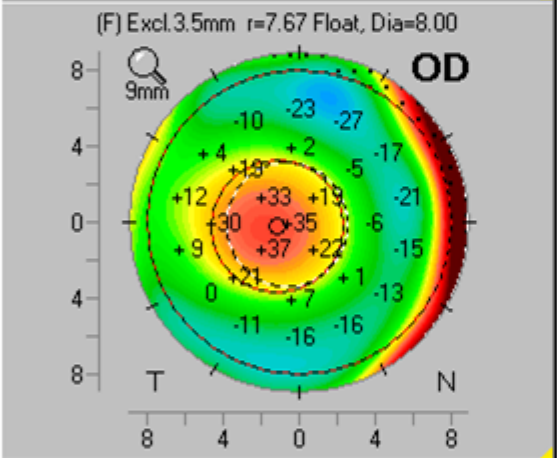
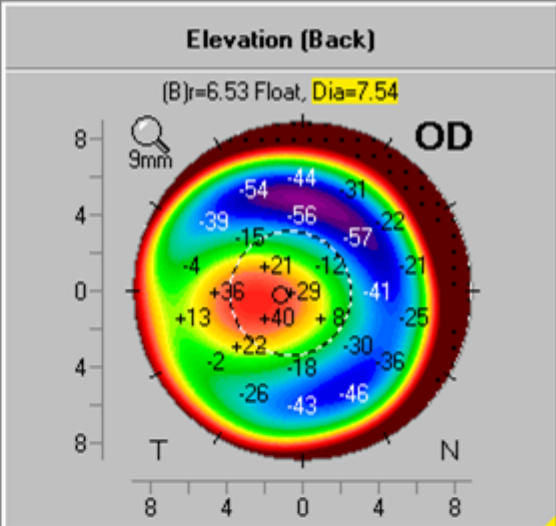
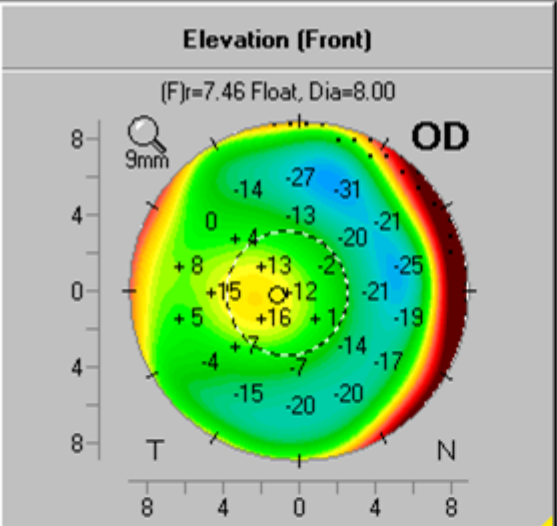
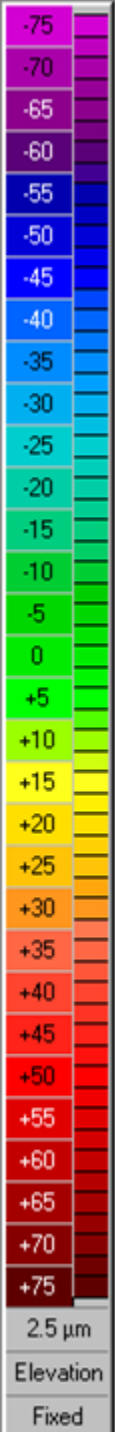


Corneal tomography

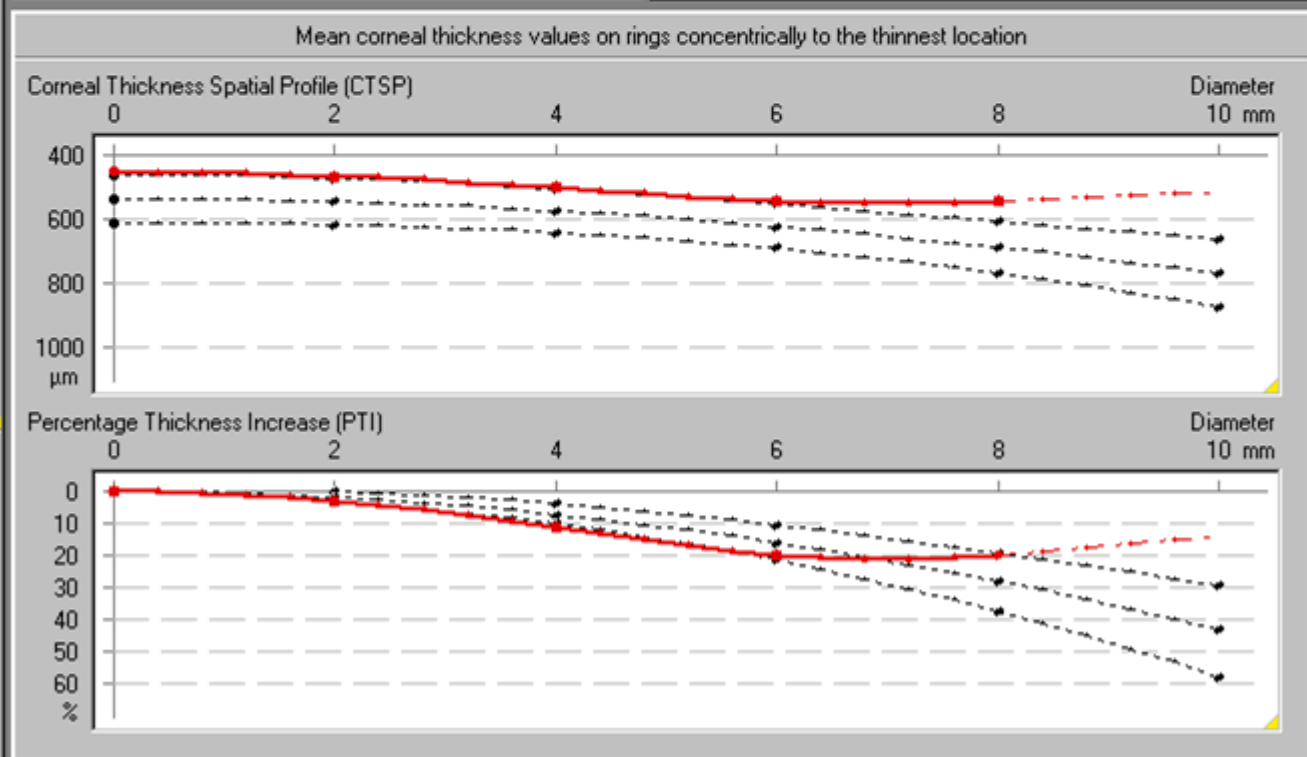
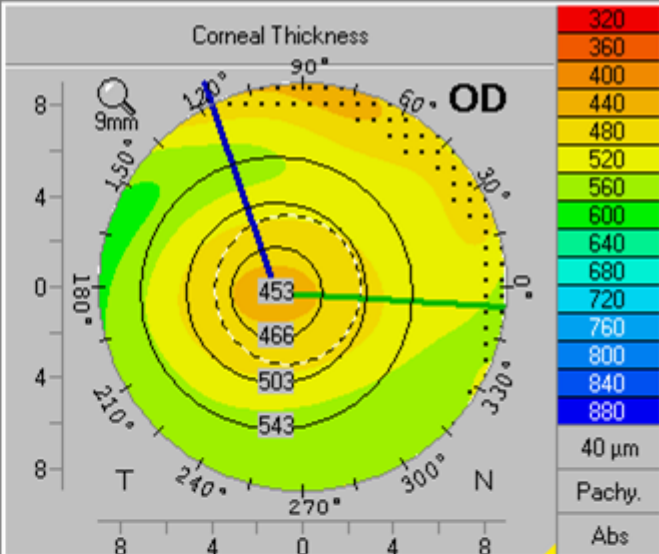
- **Prevalence of corneal tomographic changes^{1,2}: 77%**
- **Clinical bilateral keratoconus: 2 patients / Subclinical: 3 pts / Suspect corneas: 16 pts (10 bil.) bilateral)**
- No statistical difference between type I and non-type I groups ($p > 0,05$)



1. Hashemi *et. al* 2016
2. Shetty *et. al* 2017



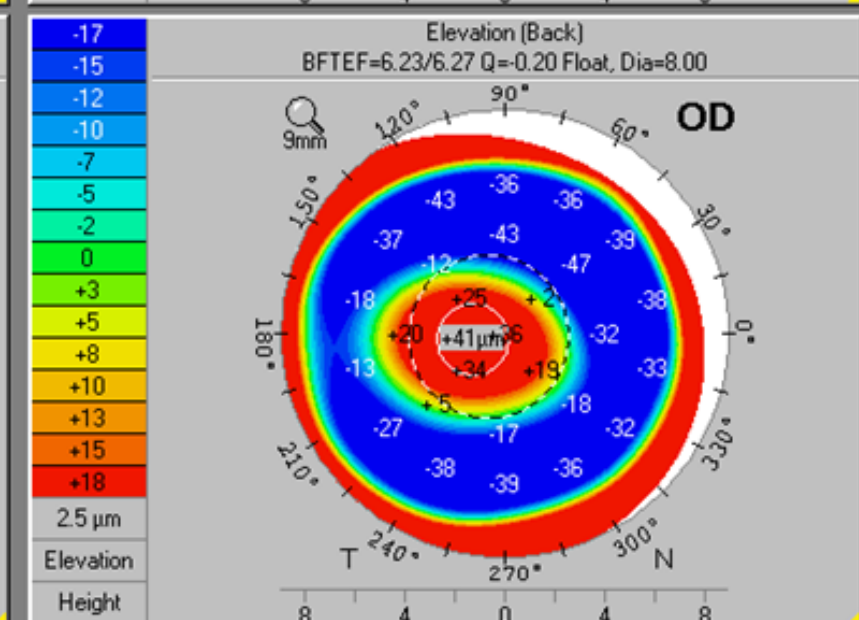
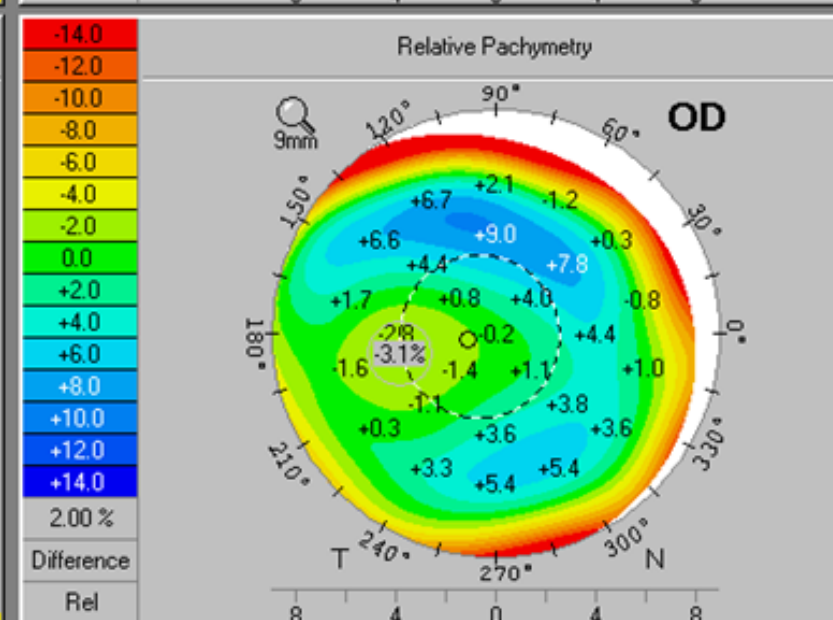
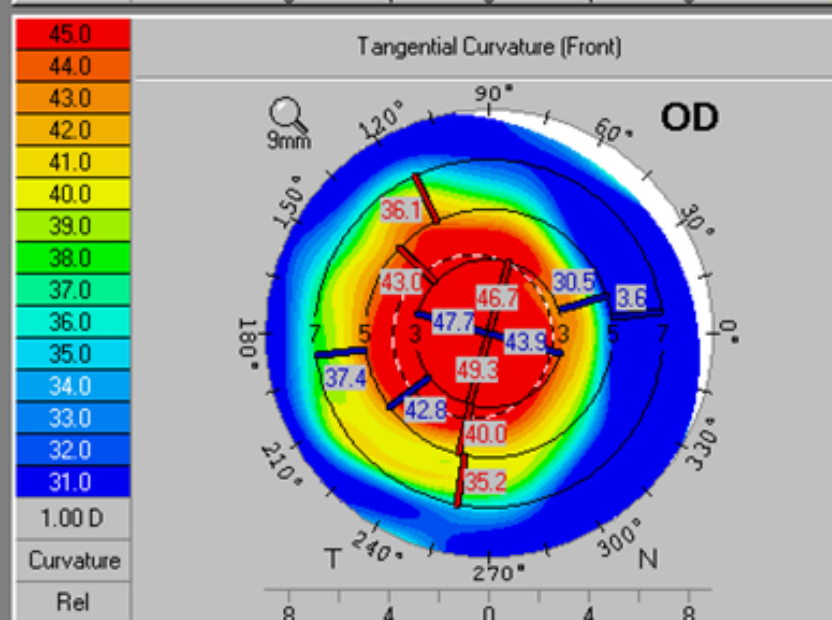
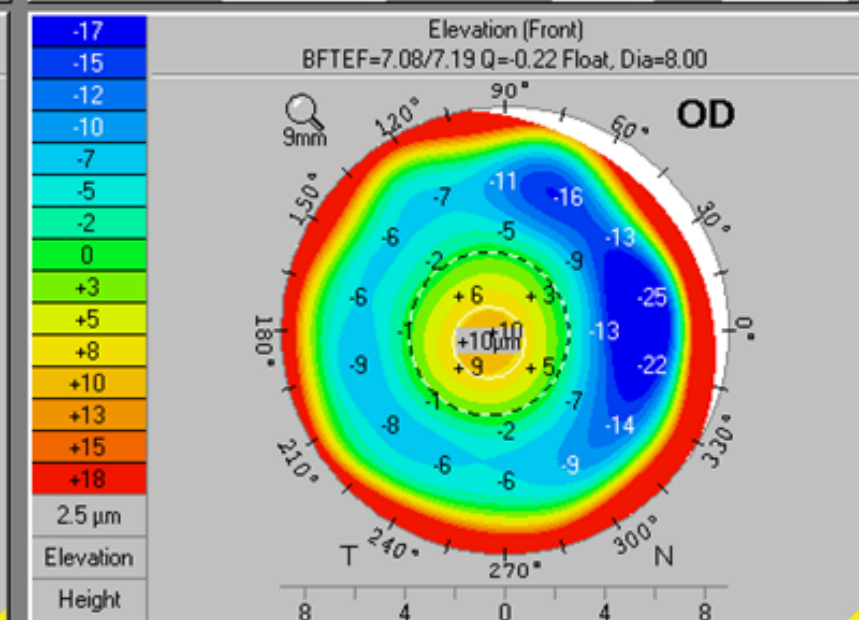
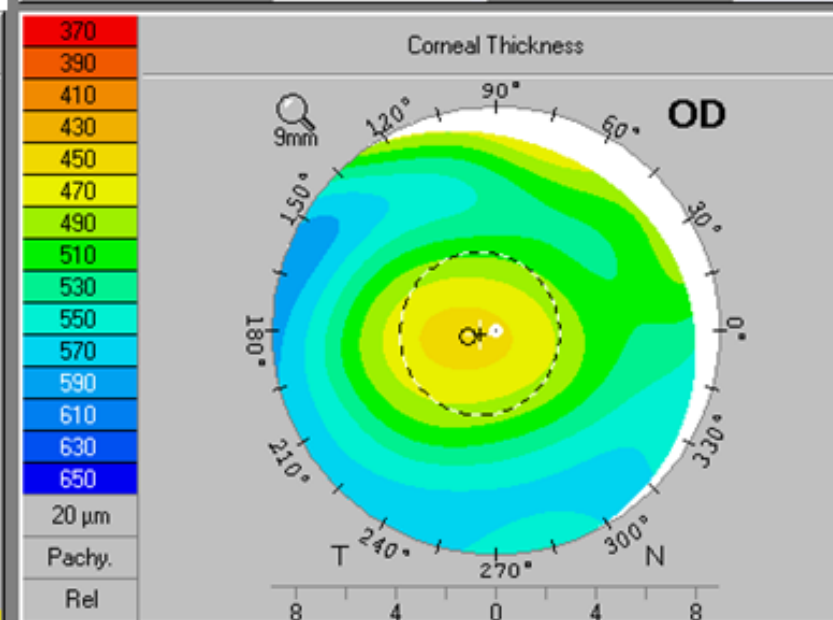
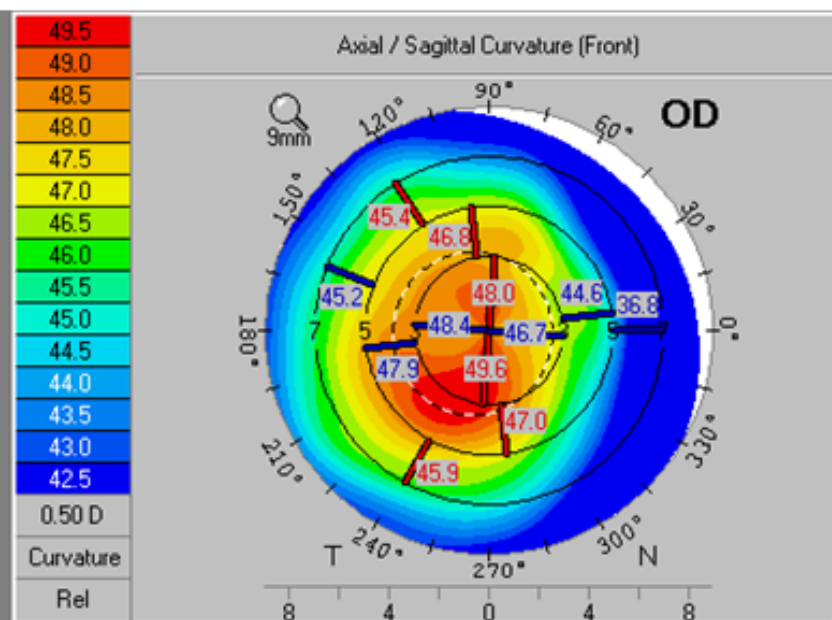
K1:	47.6D	Δvie:	176.7°
K2:	48.8D	Q-val:	-1.35
KMax:	49.8D	f6mm)	OK
		QS:	
Pachy Thin. Locat.:			453µm
Dist. Apex-Thin.Loc.:		IT	0.59mm
F.Ele.Th:	17µm	B.Ele.Th:	41µm
Progression Index:			
Min:	0.92	Max:	1.81
Avg:	1.35	ARTmax:	250



Reference Database:	<input checked="" type="radio"/> Myopic/Normal	<input type="radio"/> Hyperopic/Mixed Cyl.	Literature								
Df:	13.85	Db:	9.80	Dp:	3.04	Dt:	2.90	Da:	2.18	D:	7.30

Equiv K-Readings 65 (4.5mm Zone)		Details	
EKR65 Flat K1:	47.61 D (161 °)	Q (6.0mm):	-1.35
EKR65 Steep K2:	48.52 D (71 °)	Total SA: Z(4+6+8.0)	-0.249 μ m
EKR65 Mean:	48.06 D	Radii Ratio (B/F):	82.0 %
Astig EKR65:	0.91 D	RMS HOA WE (6mm):	0.859 μ m

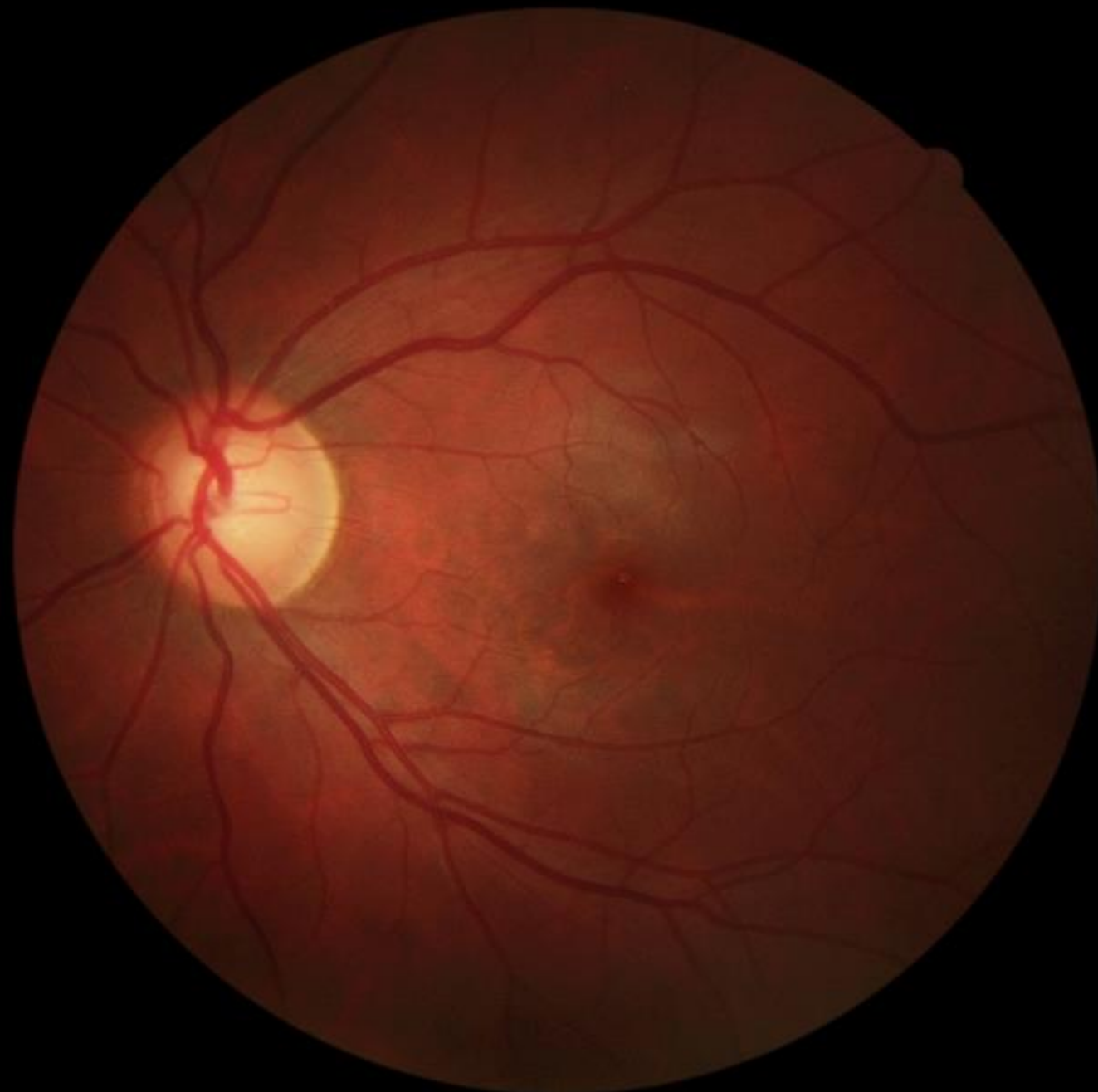

Pupil Dia:	+ 3.24 mm	x: 0.33 mm T	y: 0.06 mm I	(rel. to VN)
HWTW:	[]	x:	y:	(rel. to VN)
Pachy Min:	○ 453 μ m	x: 0.58 mm T	y: 0.13 mm I	(rel. to VN)
Est. Pre-Refr. Km:	48.6 D	Refr. Change:	-0.4 D	
A. C. Depth (Ext.):	2.58 mm	Chord μ :	0.34 mm	QS: OK



Glaucoma

- **Only 1 patient has been diagnosed with glaucoma...**

... But she has active Behçet's disease-associated uveitis

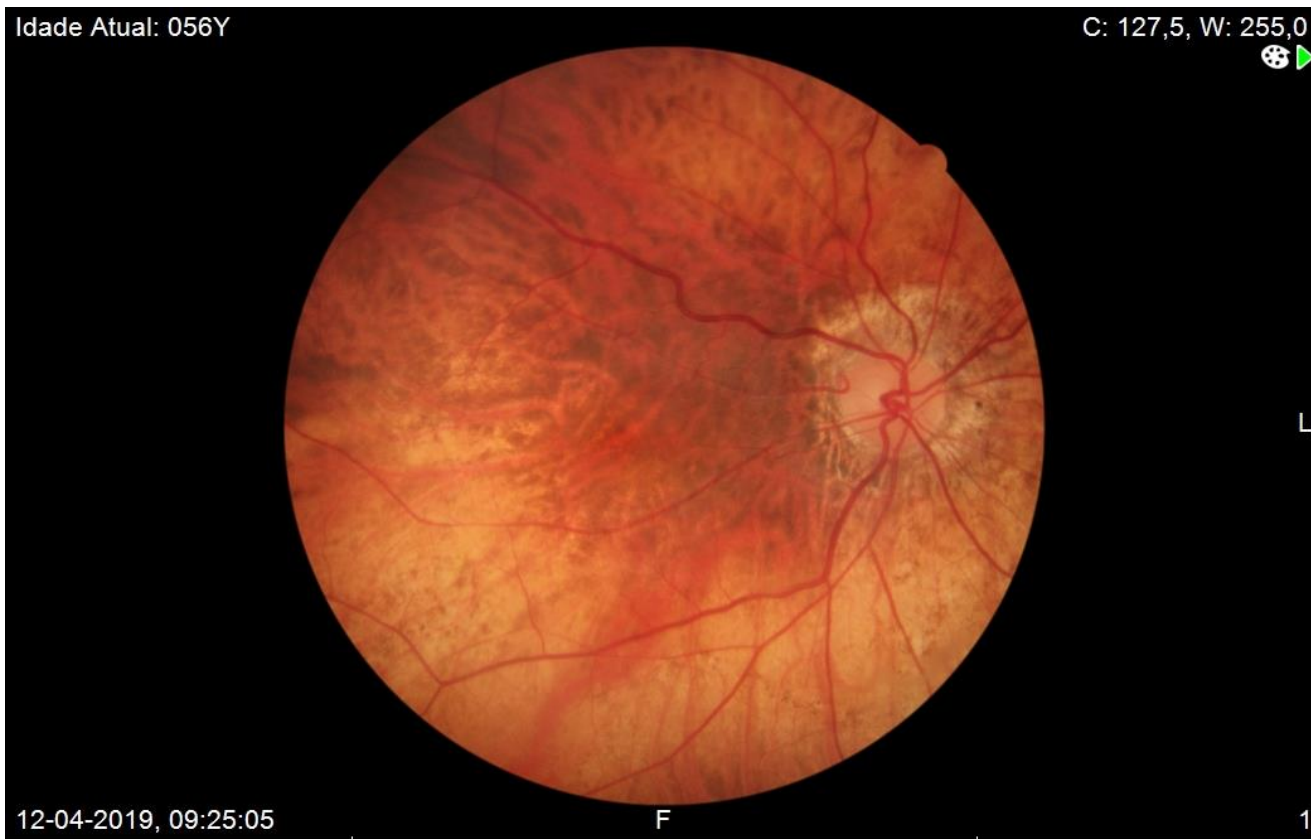

L

Retinal changes

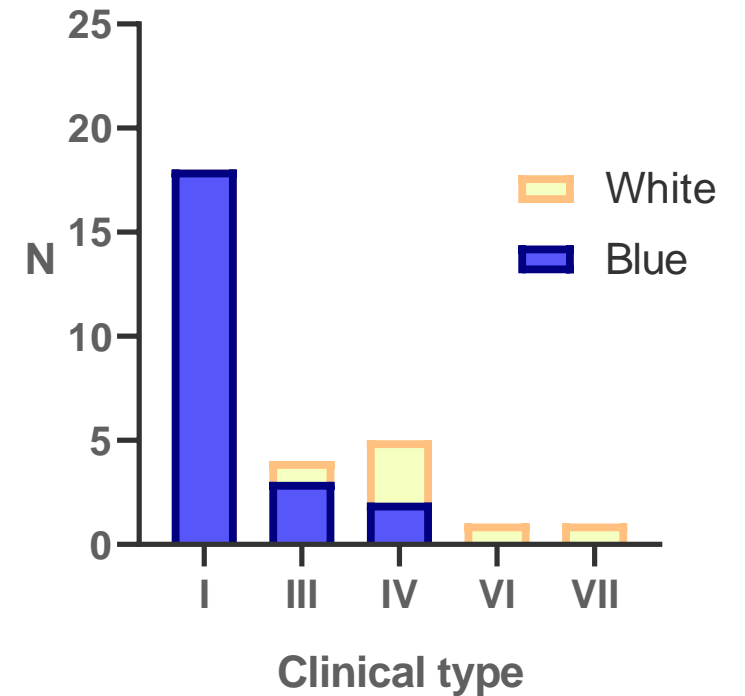
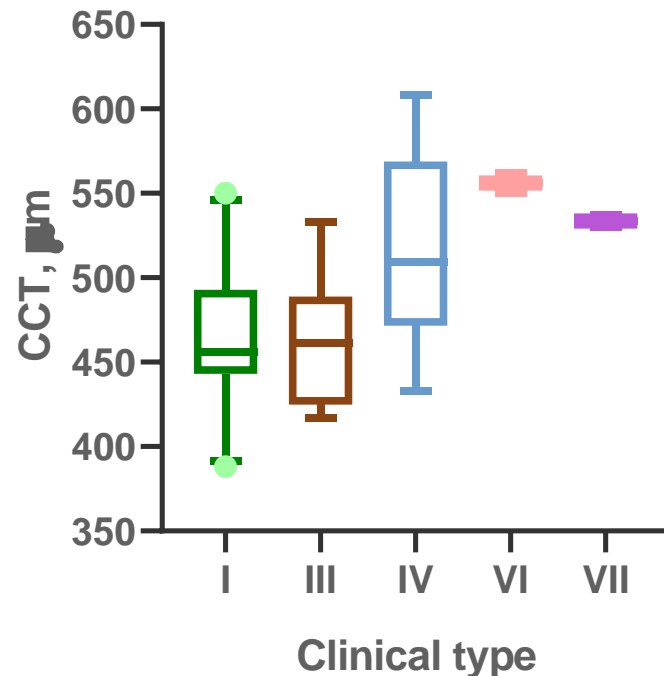
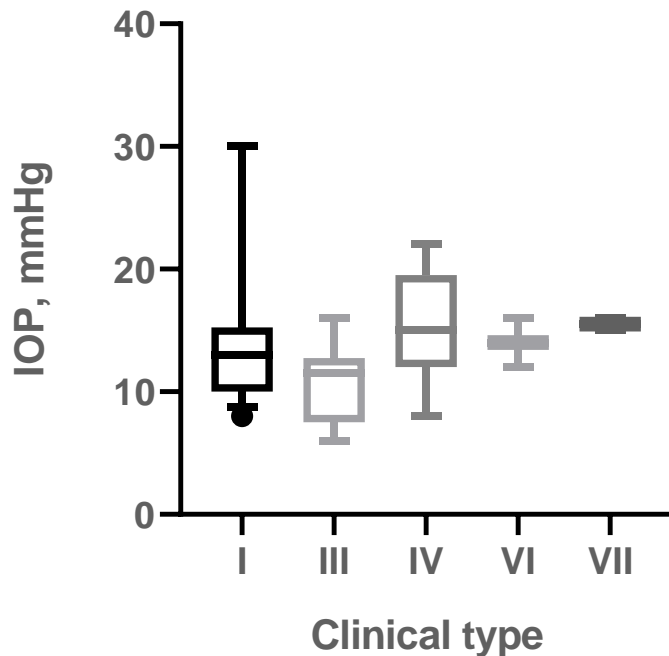
- **No relevant segment changes were detected**

... Other than **chorioretinal atrophy** associated with **high grade myopia**



Discussion

- **The majority of patients were OI type I and COL1A1 was the most common causative gene**
 - Clinical validity of these findings is stronger in type I disease
 - Type I and type III populations seem similar (IOP, CCT, blue sclerae)



Discussion

- **BCVA was moderately reduced**, and there was a **high incidence of high-grade ametropia**
 - Do collagen anomalies affect the axial length of the eye?
- **Reduced CCT is an hallmark of ocular disease in OI**
 - Correlates negatively with IOP and is more associated to type I disease and with blue sclerae
 - What is its usefulness in diagnosis?¹
 - Is it a risk factor for the development of glaucoma?²
 - **The COL1A1 gene has been associated with several forms of glaucoma³**
- **How is the relationship between blue sclerae and CCT relevant?**
 - Is it dependent on the *continuity* of thinning of the sclerocorneal layer?
 - Or is it best explained by the molecular changes particular to OI type I?

1. Hald *et al.* 2018
2. Congdon *et al.* 2006
3. Mauri *et al.* 2016



Discussion

- **Diagnosis of glaucoma in OI patients presents a clinical challenge**
 - **Lower IOPs and lower CCTs**
 - **Do the collagen changes in the sclerocorneal layer affect the way cupping develops?**
 - Since we did not perform posterior segment OCT or SAP the epidemiology of glaucoma in this population may be **underestimated**

Discussion

- **Diagnosis of glaucoma in OI patients presents a clinical challenge**
 - **Lower IOPs and lower CCTs**
 - **Do the collagen changes in the sclerocorneal layer affect the way cupping develops?**
 - Since we did not perform posterior segment OCT or SAP the epidemiology of glaucoma in this population may be **underestimated**

Discussion

- **There was a significantly high prevalence of tomographically abnormal corneas...**

... However

- There was **no significant difference between OI clinical types**
- There was **no significant difference in BCVA between abnormal and normal corneas**
- **Are current keratoconus tomographic screening indices^{1,2} applicable in this populations?**

1. Hashemi *et. al* 2016

2. Shetty *et. al* 2017



See, Hear, Smile!

Topical Meeting on Osteogenesis Imperfecta

TALLINK HOTEL - RIGA - LATVIA

14TH - 15TH OF JUNE 2019

THANK YOU FOR YOUR ATTENTION!

rafaelcbarao@gmail.com



CENTRO HOSPITALAR
LISBOA NORTE, EPE

