



Failure on clinical image quality criteria in digital mammography – how can radiographers do better?

Cláudia Reis^{1,2}, Mário Oliveira^{2,3}, Ana Pascoal⁴, João Alves³

¹ Escola Superior de Tecnologia da Saúde de Lisboa, Av. D. João II, 1990-096 Lisboa, Portugal

² Faculdade de Engenharia, Univ. Católica Portuguesa, E Octávio Pato, 2635-631 Rio de Mouro, Portugal

³ Instituto Superior Técnico, Campus Tecnológico e Nuclear, Laboratório de Protecção e Segurança Radiológica 2695-066 Bobadela LRS, Portugal

⁴ Medical Engineering and Physics, King' s College Hospital, Denmark Hill, London, London SE59RS, United Kingdom



Outline

- Justification
- Objectives
- Methods
- Results & Discussion
- Conclusions



Breast cancer in numbers

Justification

4500 new cases per year

Objectives

1500 deaths per year (female)

Methods

1%  (male)

Results & Discussion

90% curable if diagnosed early

Conclusions

Image quality

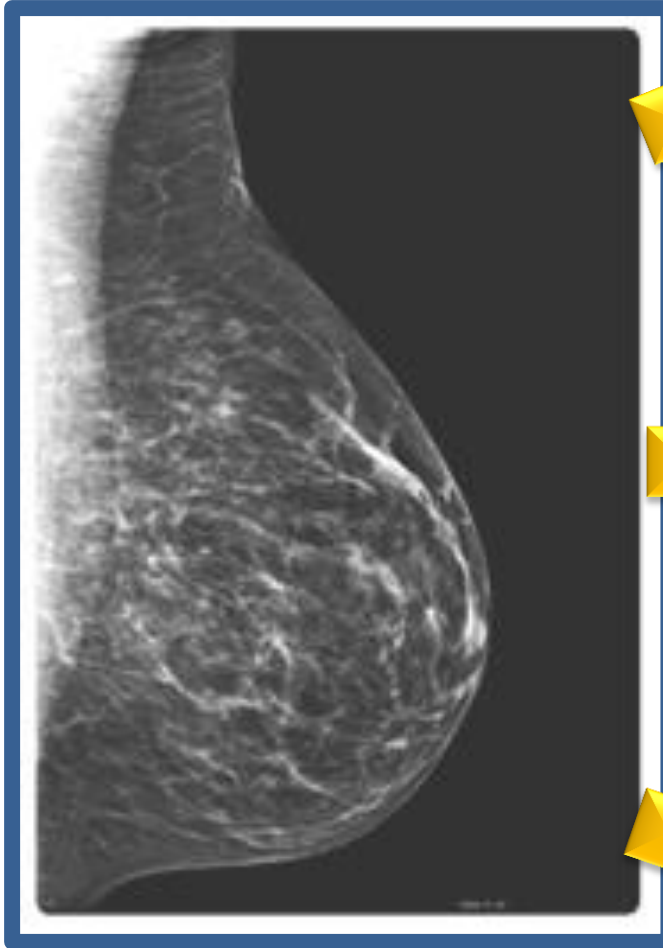
Justification

Objectives

Methods

Results &
Discussion

Conclusions



Subtle X-ray attenuation properties between normal and abnormal tissues.

The EUREF protocol recommends the assessment of IQ provided by digital mammographic systems.

9 tests for assessing the quality of the acquired image including clinical IQ breast positioning criteria.



Objectives

- Evaluate clinical image quality criteria acquired with digital mammography (PGMI)
 - P (Perfect)
 - G (Good)
 - M (Moderate)
 - I (Inadequate)
- Assess density

Justification

Objectives

Methods

Results &
Discussion

Conclusions



Image Quality

- IQ assessed on the acquisition monitor (as radiographers do)
- P (Perfect) – all criteria achieved
- G (Good) – 1 failure
- M (Moderate) – 2 failures
- I (Inadequate) – 3 or + failures

Justification

Objectives

Methods

Results &
Discussion

Conclusions

Image Quality

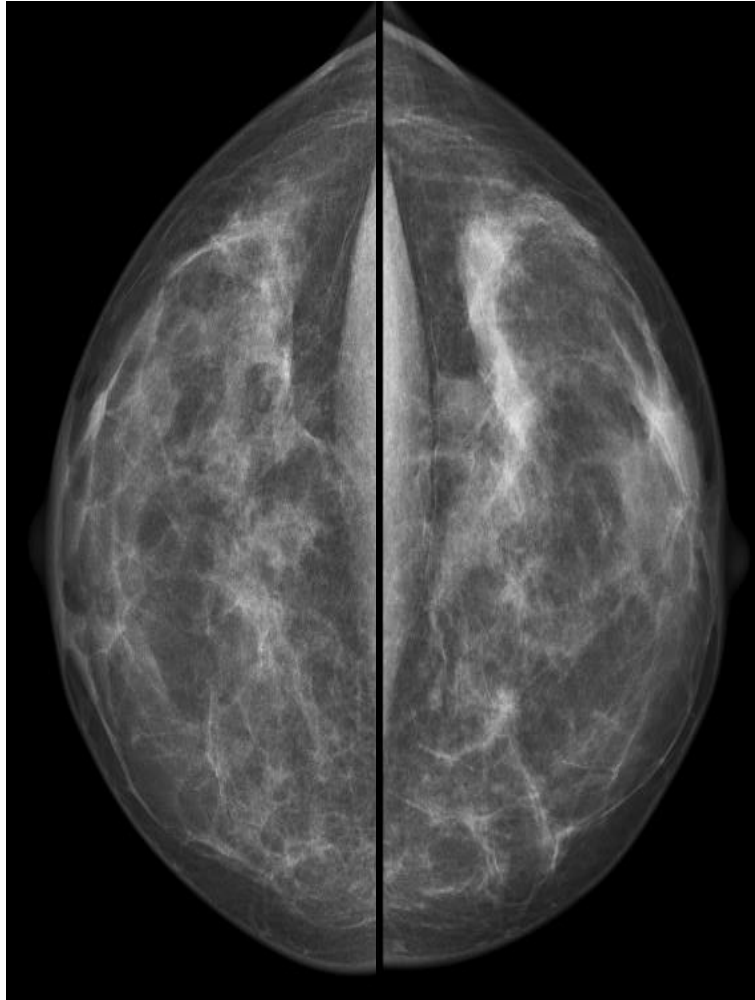
Justification

Objectives

Methods

Results &
Discussion

Conclusions



Cranio-caudal (CC) view

The medial border of the breast is shown;

As much as possible – outer quadrants;

If possible, the pectoral muscle shadow.

Adequate exposure parameters;

Both images should be symmetrical;

Nipple in profile;

Absence of skin folders;

Correct patient identification;

Absence of movement.

Image Quality

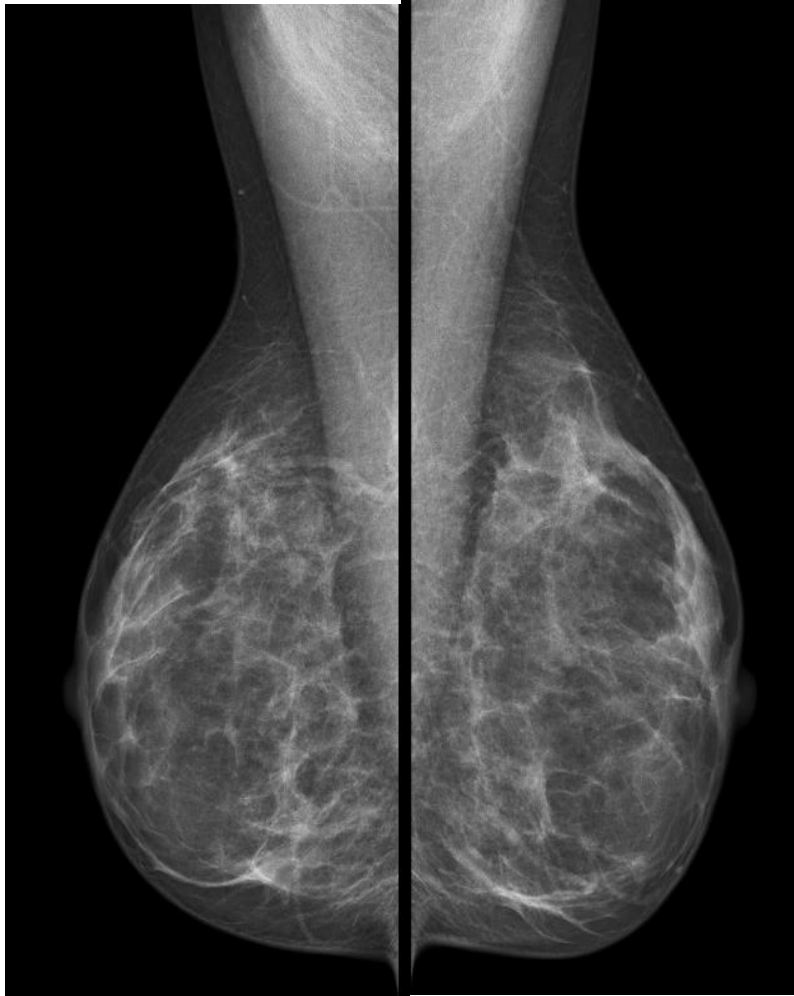
Justification

Objectives

Methods

Results &
Discussion

Conclusions



Mediolateral (MLO) view

All the breast tissue clearly shown;

Pectoral muscle to nipple level;

Inframammary angle clearly demonstrated.

Adequate exposure parameters;

Both images should be symmetrical;

Nipple in profile;

Absence of skin folders;

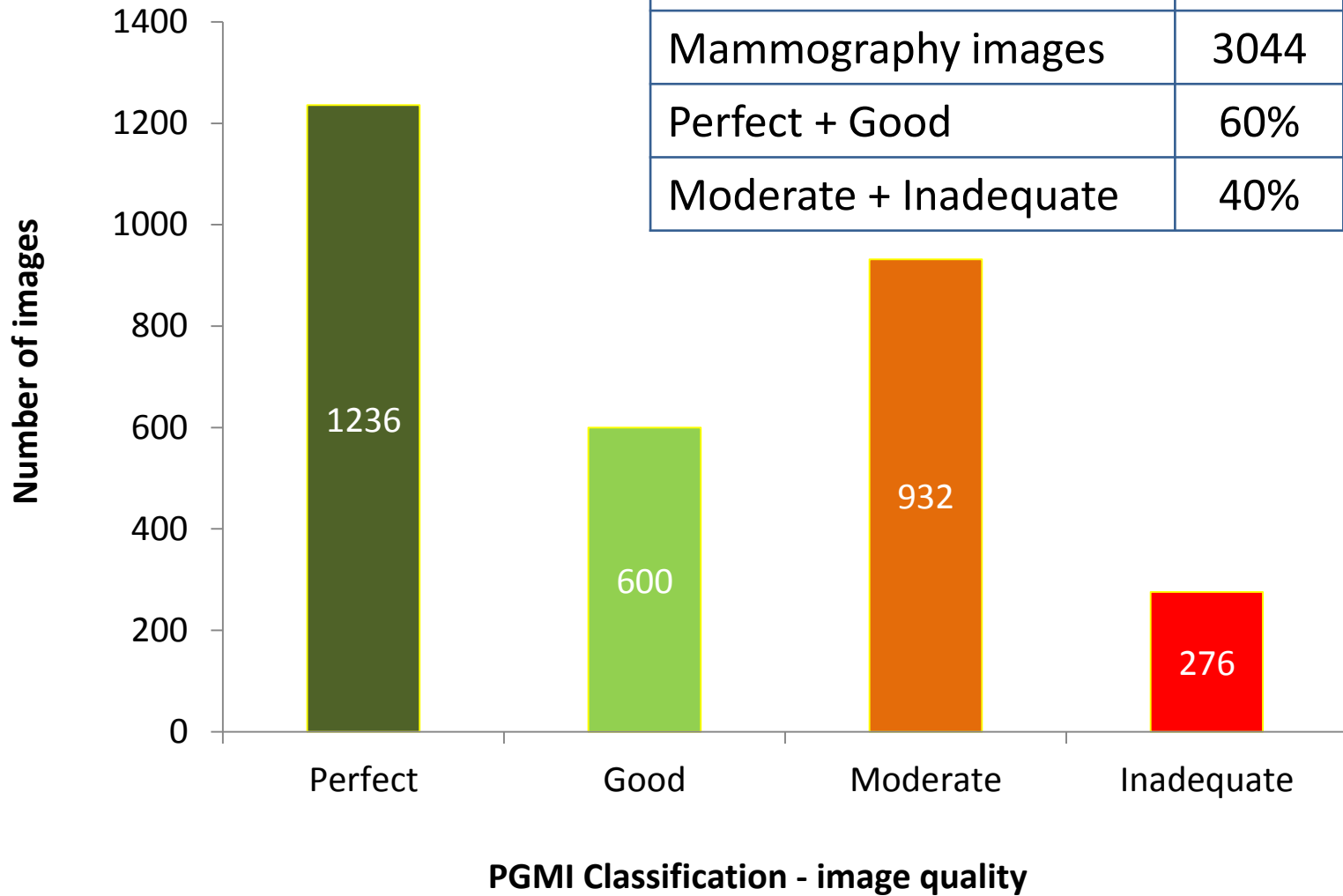
Correct patient identification;

Absence of movement.



Image Quality

	Total
DR systems	13
Mammography images	3044
Perfect + Good	60%
Moderate + Inadequate	40%



Justification
Objectives
Methods
Results & Discussion
Conclusions



Image Quality

Failed clinical criteria

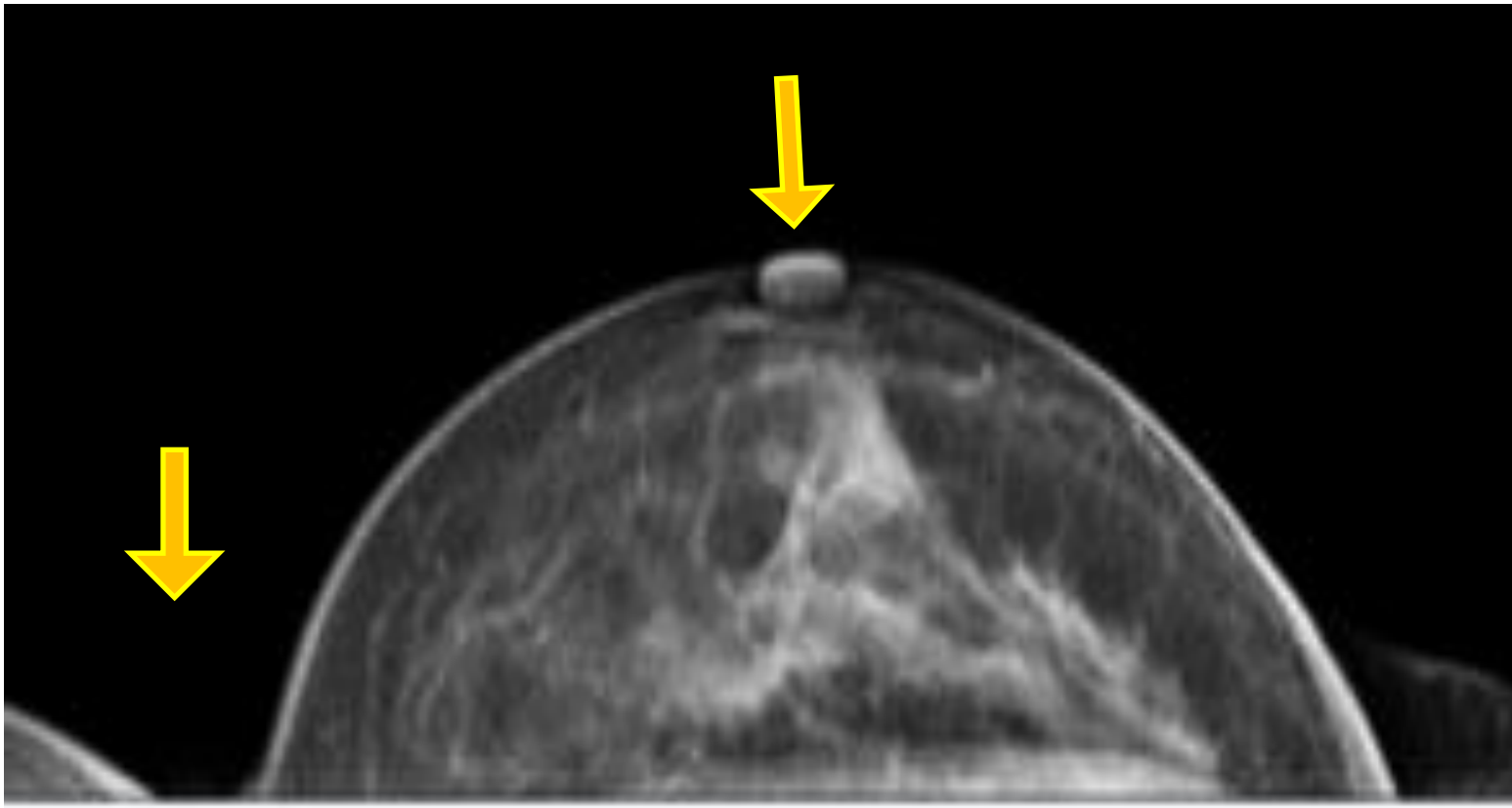
Justification

Objectives

Methods

**Results &
Discussion**

Conclusions



Failures

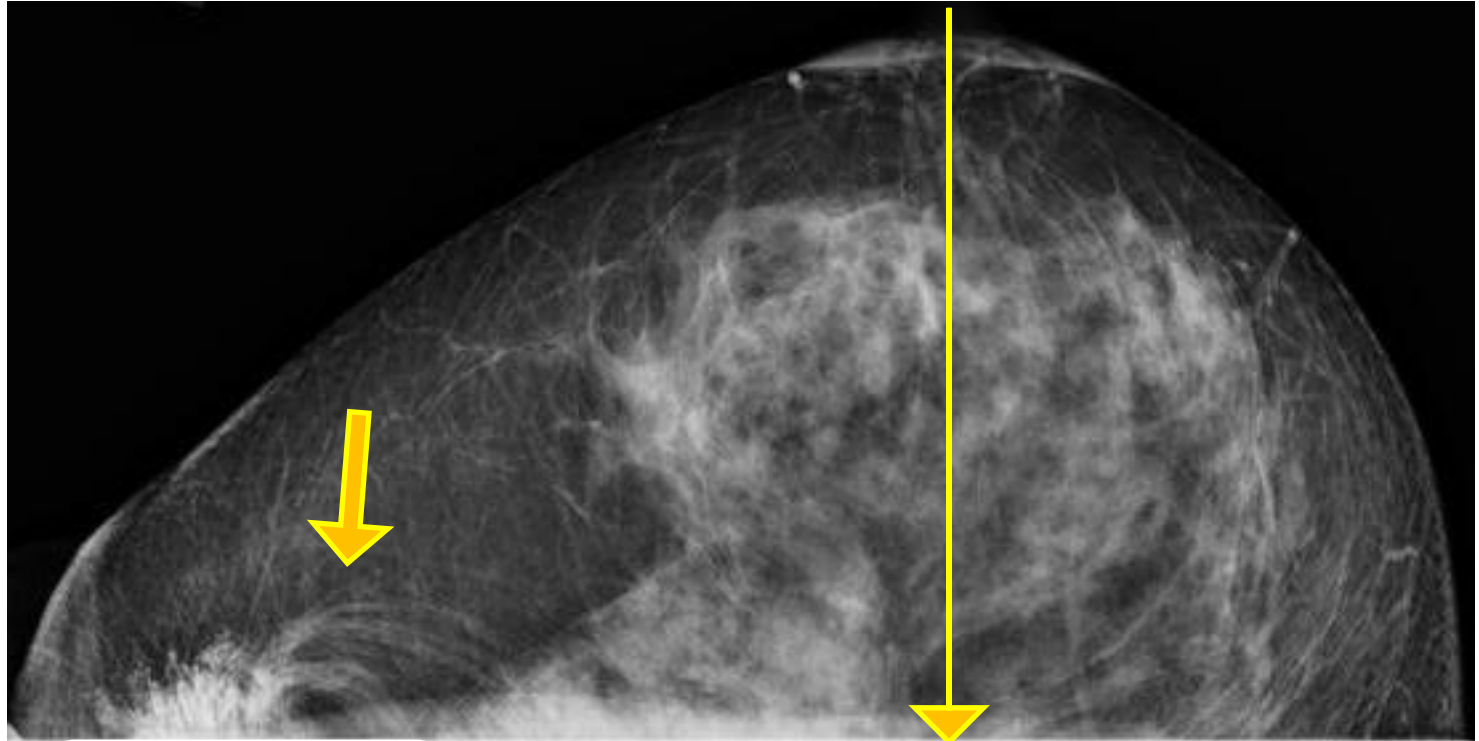
- Nipple
- Contralateral breast

Corrective Actions

- Patients help – remove CLB
- Compression technique

Image Quality

Failed clinical criteria



Failures

- Quadrants asymmetry
- Hair

Corrective Actions

- Patients help – remove hair
- Positioning technique

Justification

Objectives

Methods

Results &
Discussion

Conclusions



Image Quality

Failed clinical criteria

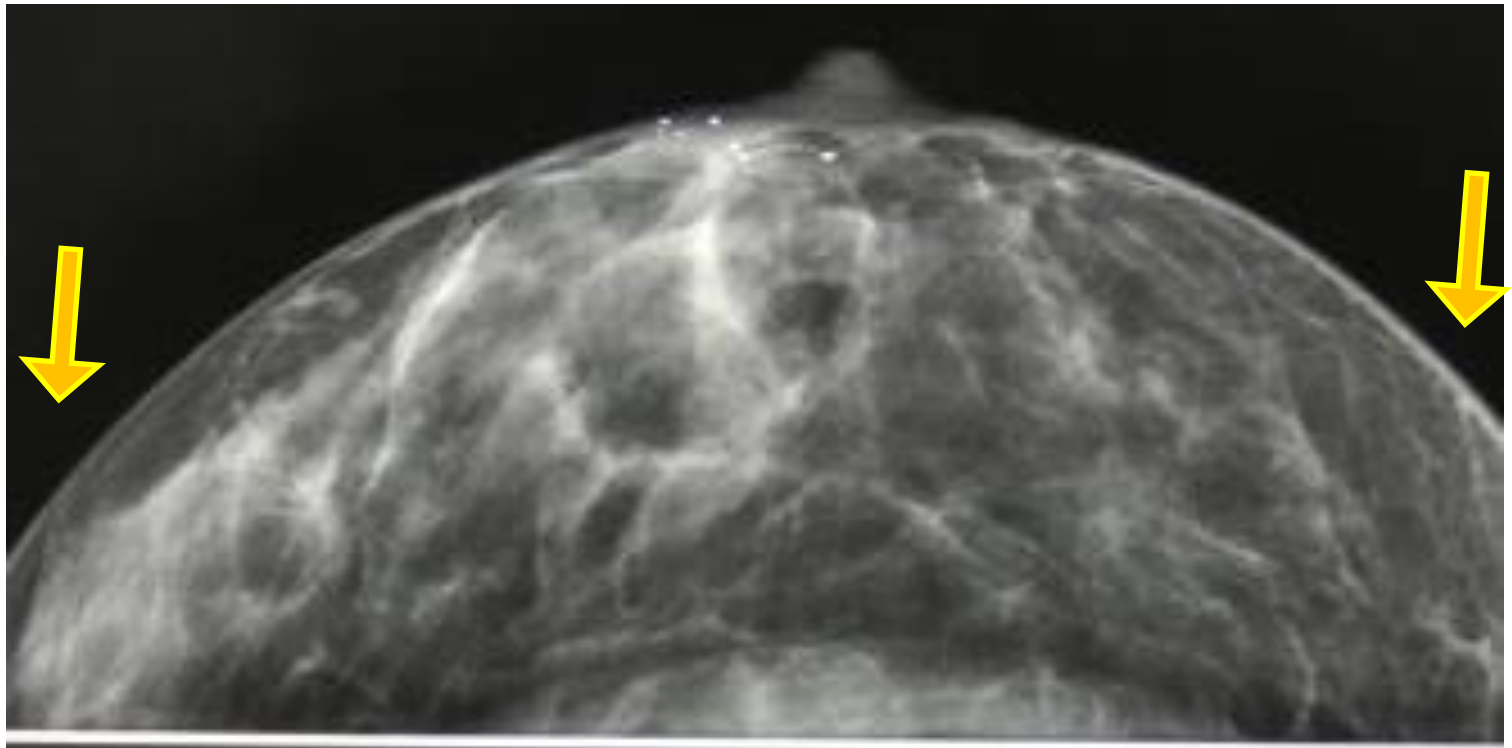
Justification

Objectives

Methods

**Results &
Discussion**

Conclusions



Failures

- Motion
- No inclusion of all tissue

Corrective Actions

- Compression force
- Positioning technique - puzzle



Image Quality

Failed clinical criteria

Justification

Objectives

Methods

**Results &
Discussion**

Conclusions

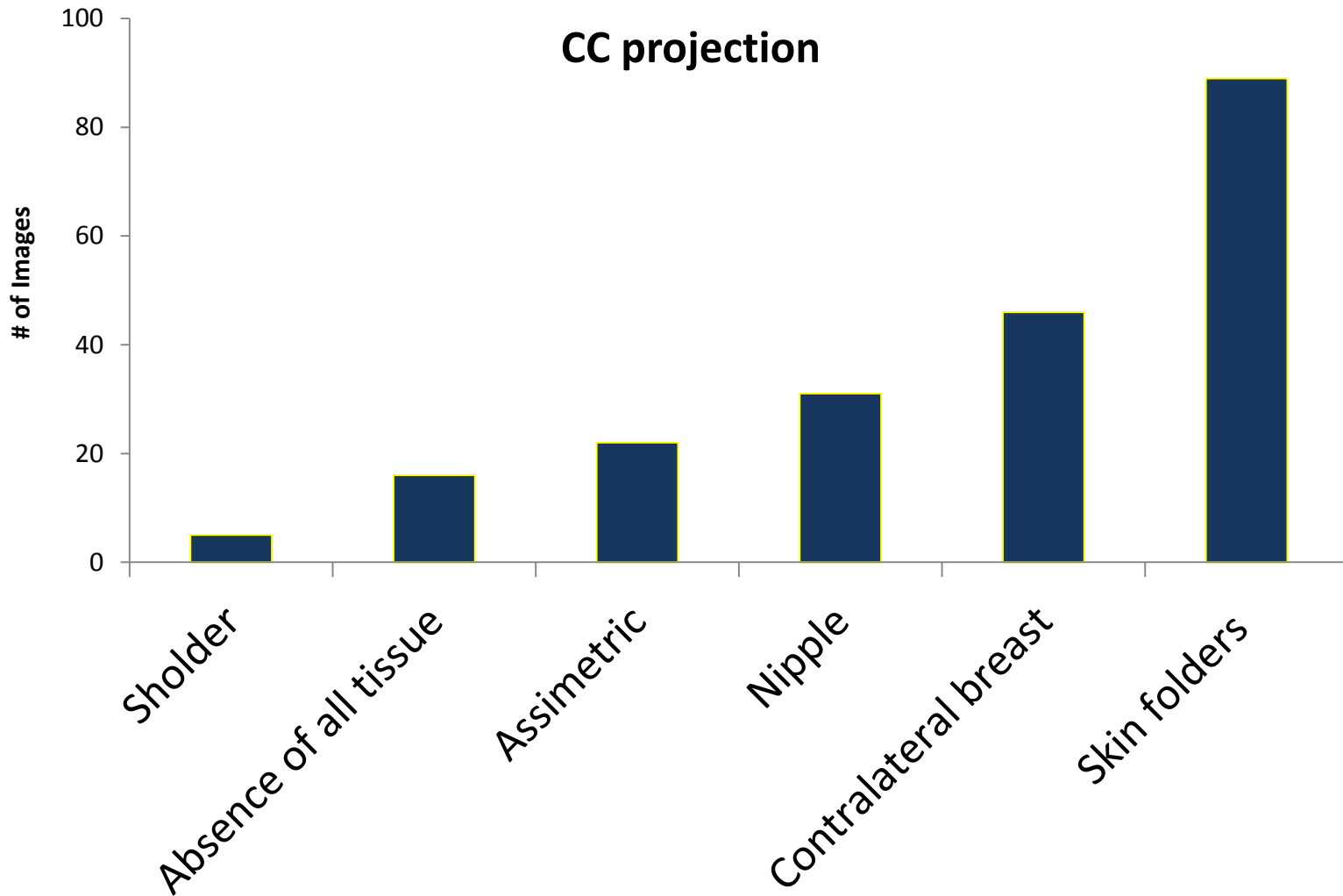




Image Quality

Failed clinical criteria

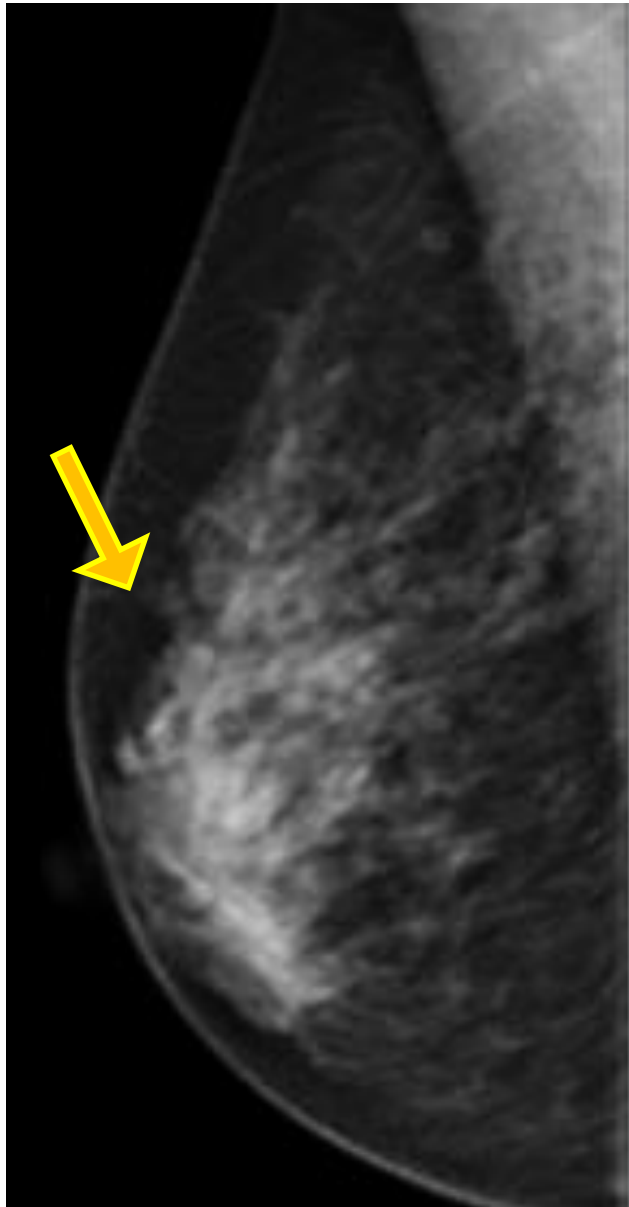
Justification

Objectives

Methods

**Results &
Discussion**

Conclusions



Failures

- Movement artifacts
- IM angle

Corrective
Actions

- Positioning technique
- Compression






Image Quality

Failed clinical criteria

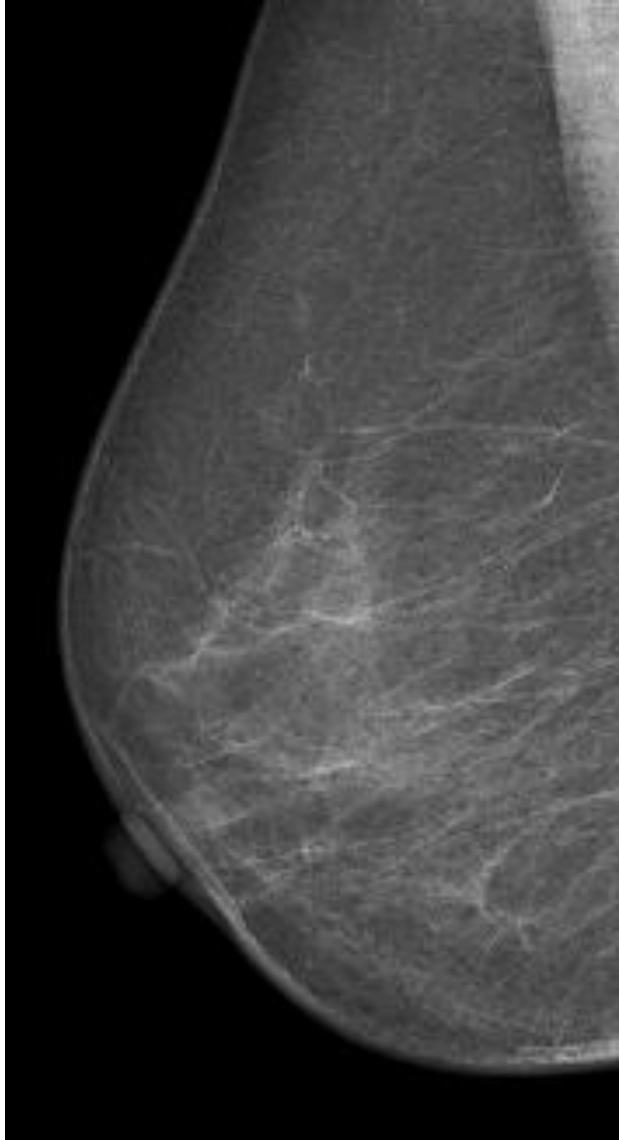
Justification

Objectives

Methods

**Results &
Discussion**

Conclusions



Failures

- MP & IM angle inclusion
- Nipple

Corrective Actions

- Compression
- Horizontalization of the breast



Image Quality

Failed clinical criteria

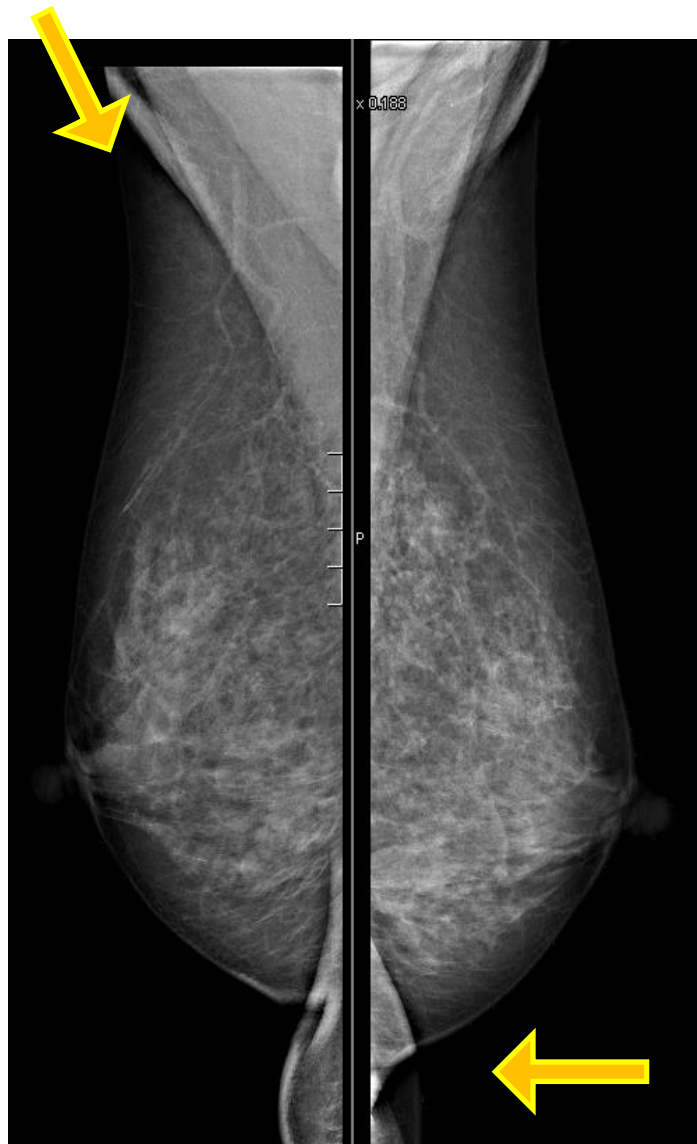Justification

Objectives

Methods

**Results &
Discussion**

Conclusions



Failures

- Folders – MP & IM angle
- Stomach superimposition

Corrective Actions

- Positioning technique
- Compression



Image Quality

Failed clinical criteria

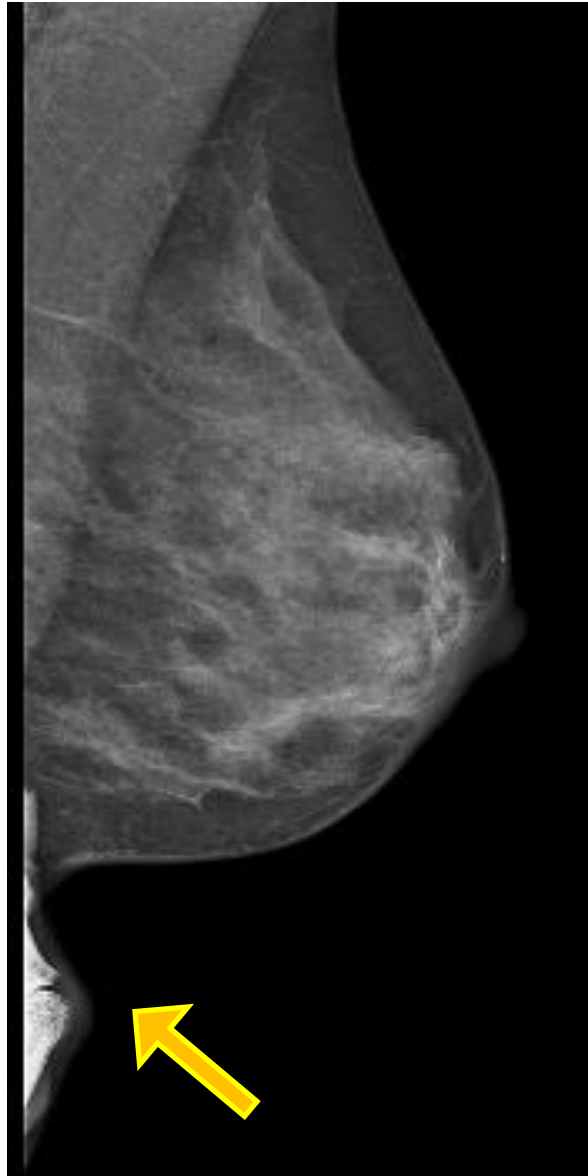
Justification

Objectives

Methods

**Results &
Discussion**

Conclusions



Failures

- IM angle inclusion
- Superimposition - finger

Corrective Actions

- Positioning technique
- Patients help



Image Quality

Failed clinical criteria

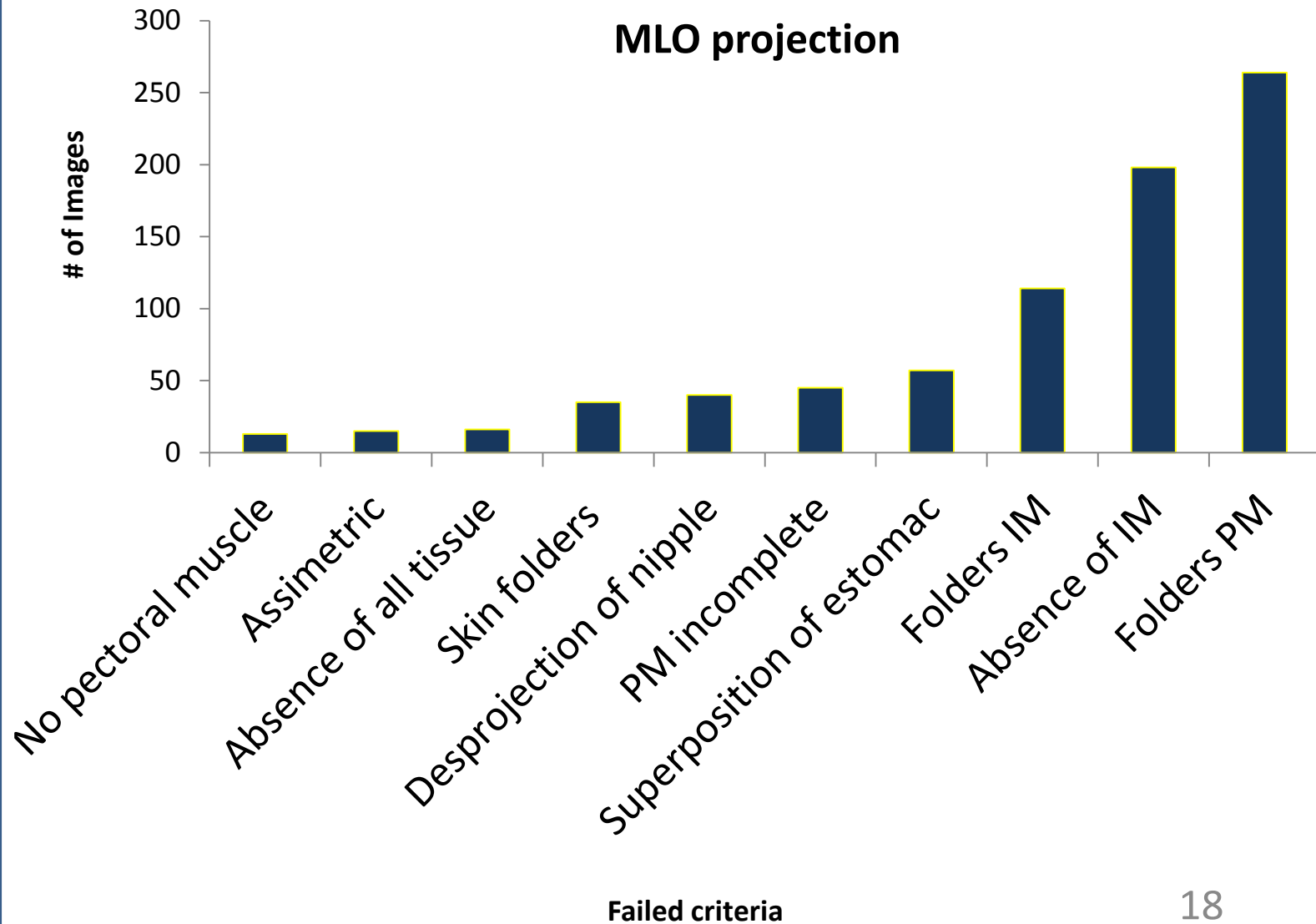
Justification

Objectives

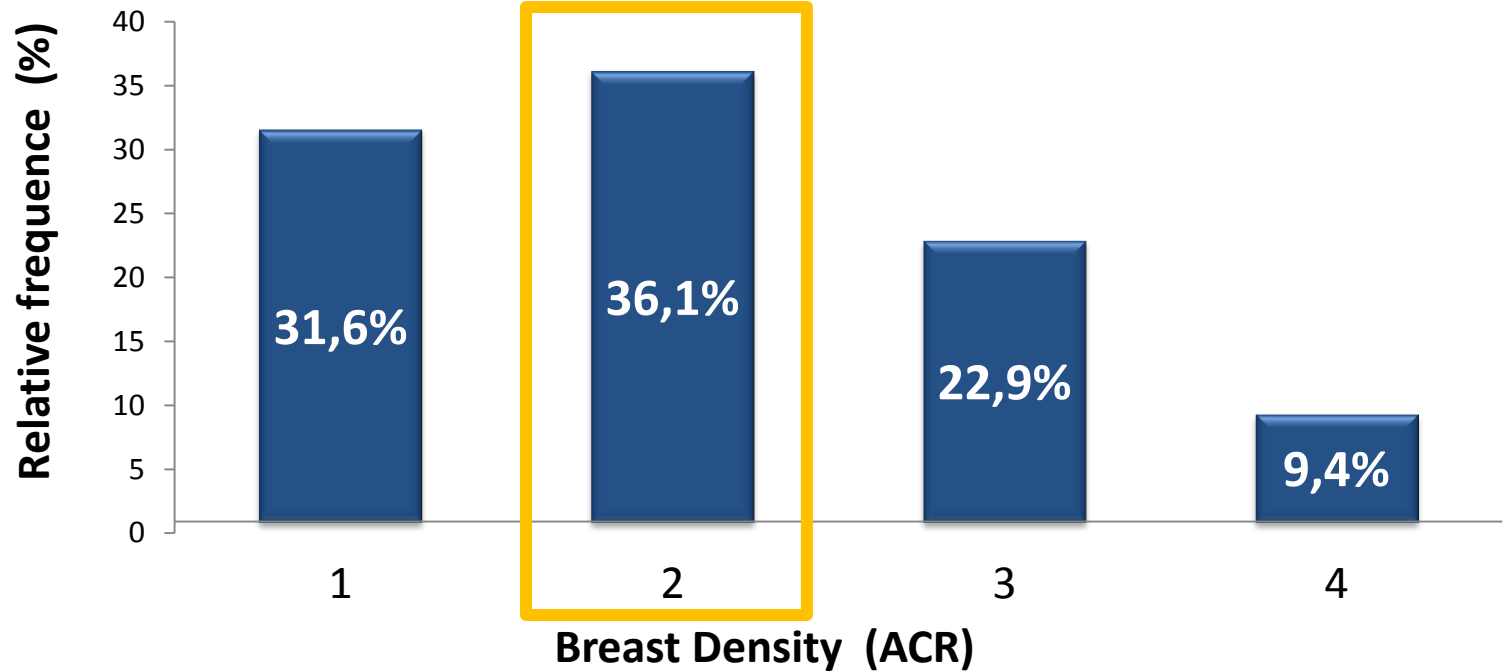
Methods

Results &
Discussion

Conclusions



Breast density



- Breast density - ACR[1,2]: fatty or with low density ($25\% < TG < 50\%$)
 - Typical breast characteristics in screening



Image Quality

- Inappropriate practice - incorrect radiographic techniques were frequently detected namely:
 - Skin folders
 - Movement
 - PM not included
- **WHY?**
 - Workload
 - Poor communication – Radiographer/Radiologist

Justification

Objectives

Methods

Results &
Discussion

Conclusions



Future work

- Correlate questionnaires data
 - Specific education and training
 - Experience in DM
 - Dedicated centers

Justification

Objectives

Methods

Results &
Discussion

Conclusions



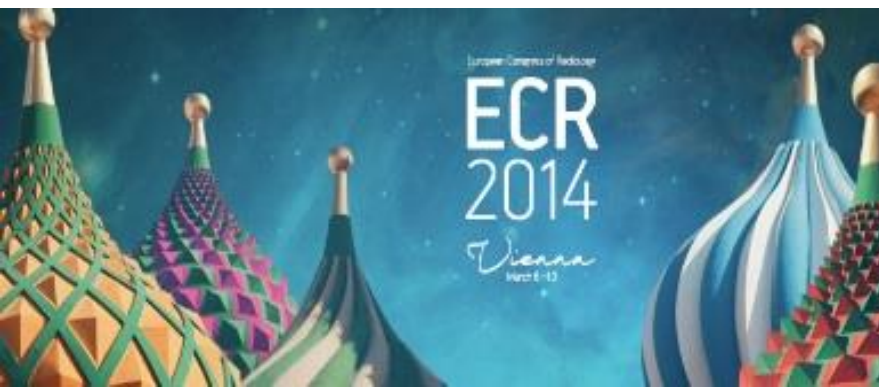Acknowledgements

CENTRO HOSPITALAR DO PORTO- HOSPITAL GERAL DE STO ANTONIO
DR. JOAO CARLOS COSTA
GABINETE DE RADIOLOGIA DE ESPINHO, DR KRUG DE NORONHA
GINOECO-SERVIÇOS MÉDICOS DE IMAGEM
GRUPO ESS _HOSPITAL DA ARRÁBIDA - VN GAIA
HOSPITAL DE SÃO JOÃO, E.P.E.
INSTITUTO PORTUGUÊS DE ONCOLOGIA DO PORTO FRANCISCO GENTIL
KRUG DE NORONHA, LDA. - PORTO
SMIC - SERV. MÉD. DE IMAGEM COMPUTORIZADA
GRUPO EUROMEDIC _C. MED. C. BRANCO - DUARTE JOAO & J
CEDILE - C. DIAG. POR IMAGEM DE LEIRIA
DIAGNOSTICUM - CLÍNICA DE DIAGNÓSTO
HOSPITAIS UNIVERSITÁRIOS DE COIMBRA
HOSPITAL STº ANDRÉ - LEIRIA
INSTITUTO PORTUGUÊS DE ONCOLOGIA DE COIMBRA FRANCISCO GENTIL
LPCC-NÚCLEO REGIONAL DO CENTRO
PINHO E MELO
STA CASA MISERICORDIA MEALHADA
CEDIMA-CENTRO IMAGIOL.MEDICA, LDA
CLIDIRAL - CLÍNICA DE DIAGNÓSTICO
CUFBELÉM - CLÍNICA STA MARIA BELÉM
CONS. RADIOLOGICO DR. SENA BATISTA
GRUPO EUROMEDIC _MANUEL ESTEVES & LUIS FRAZAO LDA GRUPO EUROMEDIC _CRT -
CENTRO DE RADIOLOGIA DE TOMAR GRUPO EUROMEDIC _DR.MESQUITA G.(FILHO)& A.-
C.R.E.AV.REPUB.S.A
GRUPO IMAG_CDRE - CENTRO DIAGNOSTICO RADIO ECOG ALGUEIRAO MEM MARTINS
HOSPITAL DA LUZ, S.A.
HOSPITAL FERNANDO FONSECA
QUADRANTES-CLIN.MEDIC.DIAGNOST.,LDA
SINDICATO DOS BANCÁRIOS DO SUL E ILHAS – CC E HOSPITAL
UNIÃO MUTUALISTA N.SRA. DA CONCEIÇÃO - MONTEPIO BARREIRO
LPCC - NÚCLEO REGIONAL DO SUL
IRE-IMAGEM RADIOLOGICA ECOGRAFICA, LDA – LISBOA
MATERNIDADE DR.ALFREDO DA COSTA

C. HOSP. BAIXO ALENTEJO
CENTRO DE RADIOLOGIA DE BEJA, LDA.
GRUPO EUROMEDIC _CDI-CLINICA DIAGNOST.IMAGEM,LDA.
HOSPITAL DO LITORAL ALENTEJANO
CENTRO HOSPITALAR DO BARLAVENTO ALGARVIO
IMAG-FERNANDO SANCHO, LDA
HPP - HOSPITAL PRIVADO SÃO GONÇALO DE LAGOS
LAGOA CENTRO _ M. CARMO A. CASTRO J. MAURICIO
R A RADIOLOGIA ALBUFEIRA LDA
MADEIRA MEDICAL CENTER
HOSPITAL ESPIRITO SANTO
GRUPO DR.CAMPOS COSTA
CLÍNICA DR.PASSOS ANGELO
HOSPITAL DO FUNCHAL
CENTRO MÉDICO DR. VERÍSSIMO DE JESUS
CLÍNICA- CLÍNICA MÉDICA DA LINHA
HOSPITAL PARTICULAR DO ALGARVE
ASSOCIAÇÃO ONCOLÓGICA DO ALGARVE
HPP - HOSPITAL SANTA MARIA DE FARO
HPP - LUSÍADAS
CUF - INFANTE SANTO
HOSPITAL S. TEOTÓNIO DE VISEU
CUF-DESCOBERTAS
CENTRO HOSPITALAR DE COIMBRA
ESS-HOSPITAL DE SANTIAGO
GRUPO ESFERA SAÚDE
HOSPITAL ST ANTÓNIO CAPUCHOS
INSTITUTO PORTUÊS DE ONCOLOGIA DE LISBOA FRANCISCO GENTIL

•No âmbito do projeto:
PTDC/SAU-BEB/100745/2008

•**PROTEC**– Programa de apoio à formação avançada de docentes do Ensino Superior Politécnico.



Thank you for your attention

claudia.reis@estesl.ipl.pt

