

Automatic Diagnosis of Liver Steatosis by Ultrasound using Autoregressive Tissue Characterization

Ricardo Ribeiro^{1,2*} and João Sanches^{1,3†}

¹Institute for Systems and Robotics

²Escola Superior de Tecnologia da Saúde de Lisboa

³Instituto Superior Técnico

Lisboa, Portugal

Abstract

Liver steatosis is mainly a textural abnormality of the hepatic parenchyma due to fat accumulation on the hepatic vesicles. Today, the assessment is subjectively performed by visual inspection.

Here a classifier based on features extracted from ultrasound (US) images is described for the automatic diagnosis of this pathology. The proposed algorithm estimates the original ultrasound radio-frequency (RF) envelope signal from which the noiseless anatomic information and the textural information encoded in the speckle noise is extracted. The features characterizing the textural information are the coefficients of the first order autoregressive model that describes the speckle field.

A binary Bayesian classifier was implemented and the Bayes factor was calculated. The classification has revealed an overall accuracy of 100%. The Bayes factor could be helpful in the graphical display of the quantitative results for diagnosis purposes.

1. Introduction

Disease processes in several different organs have been shown to be accompanied by changes in ultrasonic scattering properties [11]. In this sense, the pulse echo data from different grain types contain distinguishable statistical regularities [10]. The microstructure of the backscattered echoes is complex, depending on the overall characteristics of the ultrasound scanner in terms of bandwidth and beamwidth, on the scattering properties of the propagation path and on

the attenuation caused by absorption, scattering, and beam spreading (diffraction effect) [10].

Hepatic steatosis arises when fat exceeds 5% of the total liver weight and it is caused by failure of normal hepatic fat metabolism [8]. This fat excess within the hepatocytes leads to an increasing on the brightness of the US image which also arises in the fibrosis and cirrhosis cases [8]. Therefore, the accurate identification of the steatosis is a difficult task. However, the increasing of hepatocytes size leads to characteristic diffraction patterns, reflected in the *speckle* field, that may be used to characterize the steatosis and differentiate from other pathologies.

The steatosis is a diffuse liver disease that usually affect all parenchyma. However, it may also affect small regions and in these cases the spatial resolution plays an important role in the detection and characterization of lesions [5].

The directional properties of the tissue lead to different directional characteristics on the *speckle* pattern. In a classical wavelet analysis of the *speckle* field, the energy of the first decomposition horizontal detail field is larger for the healthy liver and smaller for the steatotic one and the contrary in the case of the vertical decomposition [4].

Here, changes on the directional properties of the *speckle* field are characterized using an *autoregressive* (AR) model and consistency with the previous results described in [4] by using wavelet analysis is shown.

The objective of this work is to design a classifier for automatic diagnosis of liver steatosis from US images where robust autoregressive parameter estimation is used.

2. Problem Formulation

The estimation of the RF envelope and of despeckled anatomic images is performed using the Bayesian methods proposed in [6] and [7], respectively. The estimated speckle field is used to extract the textural features needed for the automatic diagnosis of the steatosis. The speckle corrupting

*Corresponding author:ricardo.ribeiro@estesl.ipl.pt

†This work was supported by Fundação para a Ciência e a Tecnologia (ISR/IST plurianual funding) through the POS Conhecimento Program which includes FEDER funds.

the US images is multiplicative in the sense that its variance depends on the underlying signal and therefore the image formation model may be formulated as follows [4]:

$$y = \eta\sqrt{f} \quad (1)$$

where f is a pixel intensity of the despeckled image, y is the pixel intensity of the RF image and η is the corresponding speckle intensity.

Features were extracted from the first order autoregressive model (AR) coefficients of the texture image, which is assumed to be a 2D random field $x(m, n)$, where $x(m, n)$ denotes the value of the random field at the location (m, n) . Then the two dimensional AR model is given by [9]

$$x(m, n) = \sum_{i=0}^p \sum_{j=0}^q a_{ij}x(m-i, n-j) + u(m, n) \quad (2)$$

where the coefficients a_{ij} must be estimated.

The values of p and q define the order of the model and $a_{0,0} = 1$. There are several algorithms described in the literature to compute AR parameters a_{ij} [1]. In this work, the least-squares algorithm is used, according to [1]. To select the order of the AR model, we use has a criterion the lowest error probability result in the detection of normal and steatotic liver, using a binary Bayesian classifier.

A Bayes classifier based on these features, was trained with data classified in two classes, *Normal*, ω_N , and *Fatty*, ω_F . It is assumed that the vector of features are multivariate normal distributed [3,12].

The Bayes factor (B) was used to measure the confidence level in the classification. In [2] it is suggested the following categorization:

(B_{FN})	Evidence against ω_N
1 to 3	<i>Not worth more than a bare mention</i>
3 to 20	<i>Positive</i>
20 to 150	<i>Strong</i>
> 150	<i>Very strong</i>

To access the severity of the steatosis, a map image was computed. In this image, $S = \{s_{i,j}\}$, each pixel, $s_{i,j}$, is

$$s_{i,j} = \begin{cases} b_{i,j} & \text{if } b_{i,j} \geq 1 \\ 0 & \text{otherwise} \end{cases}$$

where $b_{i,j} = \frac{P(x_{i,j}|\omega_F)}{P(x_{i,j}|\omega_N)}$ is the Bayes factor.

3. Experimental Results

We use the same dataset of [4], corresponding to 20 liver ultrasound images from 10 patients (5 with fatty livers and

5 with normal livers). Radiologists made the classification and complementary indicators were obtained from laboratorial analysis. From each image, one ROI of 128 by 128 pixels along the center line have been selected. The leave-one-out crossvalidation method was used in the training process due to the lack of data.

The first goal was to establish the optimal AR order for classification purposes and then used the AR coefficients has features. Like in [10], the results displayed in Table 1, confirm that the low-order AR model can characterize the classes in study. The error probability (PE) increases with the order of the model up to the 4th. For higher orders the PE decreases, e.g., the 6th order have a PE of 20%. Nevertheless, the two best results are the 1st and 2nd order models where the PE is 0%. These results show a sensitivity and specificity of 100% in detecting this type of disease, which is a promising result. The first order AR model is therefore adopted.

AR Model	Error prob.	Accuracy prob.
1 st order	0%	100%
2 nd order	0%	100%
3 rd order	25%	75%
4 th order	50%	50%
5 th order	40%	60%
6 th order	20%	80%

Table 1: Results of the Bayesian classifier according to the AR model order

According to the Figure 1, we can conclude that the AR coefficient a has higher values in the pathologic class than in the normal one, with mean value of 0,5881 and 0,2558, respectively, and variance of 0,007 and 0,003, respectively. On the opposite, the AR coefficient c has a lower value in the pathologic class. This fact is consistent with the values of the mean and variance for each class: pathologic class - 0,7162 and 0,0012, respectively; normal class - 0,8064 and 0,0009, respectively. Despite the fact that the AR coefficient b has the higher value of variance (0,0044) in the normal class, it has a good sensitivity for the changes between classes. These results are consistent and are according to [10], where using the 3 features will provide the best classification outcome.

We believe that the Bayes factor could be helpful in the graphical display of the quantitative results for diagnosis purpose, since it gives the medical doctor an idea of how well the evidence support the fact that it is a steatotic liver and where are the critical areas within the liver. This was accomplished by overlapping the original US image and the map of colors corresponding to the Bayes factor categories. Figure 2 shows the original US image (a) colored with a color code extracted from the mapping image S (b).

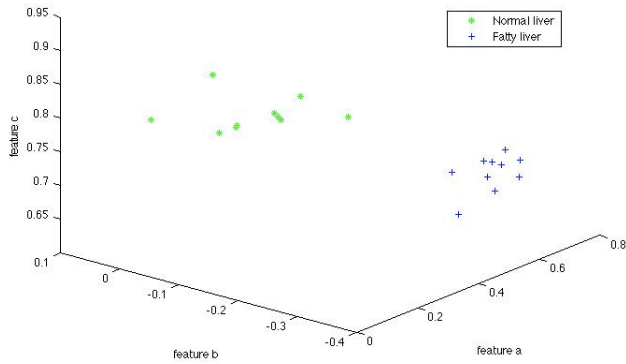


Figure 1: Distribution of liver classes (normal and fatty) according to the selected features.

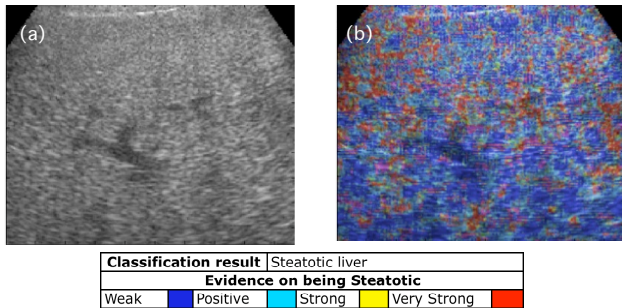


Figure 2: Graphical display of the Bayes factor results. (a) original US liver image and (b) overlapping result for diagnosis purpose

4. Conclusions

In this work a textural analysis of the liver parenchyma is proposed to help in the diagnosis of the steatosis. A first order autoregressive model is used to describe the *speckle* field extracted from the estimated envelope RF signal from the observed ultrasound image.

The vector of the estimated coefficients, performed with the least squares method in a window basis, is used to discriminate healthy and pathologic regions of the hepatic parenchyma. Additionally, the Bayes factor is mapped in the original image providing useful information to the medical doctor about the confidence of the classification.

Results obtained from real data have shown the ability of the method to detect the disease. The main goal is to put together the estimated AR coefficients computed from the *speckle* field with other features, not only textural, to obtain a reliable classifier/quantification algorithm for the steatosis.

The major drawback of this study was that the dataset size was small and further studies are needed before any

definitive conclusions can be made.

References

- [1] J.-M. Girault, F. Ossant, A. Ouahabi, D. Kouame, and F. Patat. Time-varying autoregressive spectral estimation for ultrasoundattenuation in tissue characterization. *IEEE Transactions on Ultrasonics, Ferroelectrics and Frequency Control*, 45(3):650–659, May 1998.
- [2] R. Kass and A. Raftery. Bayes factors. *Journal of the American Statistical Association*, 90(430):773–795, June 1995.
- [3] A. Mojsilovic, S. Markovic, and M. Popovic. Characterization of visually similar diffuse diseases from b-scan liver images with the nonseparable wavelet transform. *Image Processing, International Conference on*, 3:547, 1997.
- [4] R. Ribeiro and J. Sanches. Fatty liver characterization and classification by ultrasound. In H. Araújo, A. M. Mendonça, A. J. Pinho, and M. I. Torres, editors, *Proceedings of the 4th Iberian Conference on Pattern Recognition and Image Analysis, IbPRIA*, Lecture Notes in Computer Science, pages 354–361. Springer, June 2009.
- [5] U. Scheipers, H. Ermert, K. Konig, H.-J. Sommerfeld, and T. Senge. Diagnostics of prostate cancer based on ultrasonic multifeature tissue characterization. *Ultrasonics Symposium, 2004 IEEE*, 3:2153–2156, August 2004.
- [6] J. Seabra and J. Sanches. Modeling log-compressed ultrasound images for radio frequency signal recovery. *Engineering in Medicine and Biology Society, 2008. EMBS 2008. 30th Annual International Conference of the IEEE*, 2008.
- [7] J. Seabra, J. Xavier, and J. Sanches. Convex ultrasound image reconstruction with log-euclidean priors. *Engineering in Medicine and Biology Society, 2008. EMBS 2008. 30th Annual International Conference of the IEEE*, 2008.
- [8] S. Sherlock and J. Dooley. *Diseases of the liver and Biliary System*. Blackwell Science Ltd, 11 edition, 2002.
- [9] P. Stathaki and A. Constantinides. Robust autoregressive modelling through higher order spectralestimation techniques with applications to mammography. *Conference Record of The Twenty-Seventh Asilomar Conference on Signals, Systems and Computers*, 1:189–193, November 1993.
- [10] T. Wang, J. Saniie, and X. Jin. Analysis of low-order autoregressive models for ultrasonic grainsignal characterization. *IEEE transactions on Ultrasonics, Ferroelectrics and Frequency Control*, 38(2):116–124, March 1991.
- [11] K. Wear, R. Wagner, and B. Garra. A comparison of autoregressive spectral estimation algorithms and order determination methods in ultrasonic tissue characterization. *IEEE Transactions on Ultrasonics, Ferroelectrics and Frequency Control*, 42(4):709–716, July 1995.
- [12] W.-C. Yeh, Y.-M. Jeng, C.-H. Li, P.-H. Lee, and P.-C. Li. Liver fibrosis grade classification with b-mode ultrasound. *Ultrasound in Medicine & Biology*, 29:1229–1235, 2003.